Interventionelle Neuroradiologie

PD Dr. Franziska Dorn

Dr. Philipp Mennemeyer

Aneurysmen

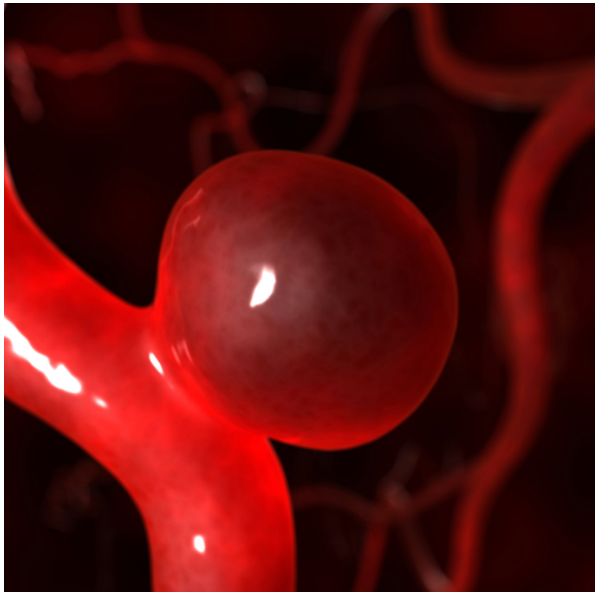

- Gefäßwandaussackung
- Prävalenz ca. 5% (in Finnland/ Japan höher)
- In der Europa mind. 20 Mio. Menschen
- Häufigste Ursache für spontane (=nicht traumatische) SAB

→Sehr hohe Mortalität (50%)/Morbidität

- Rupturrisiko 2-6% / Jahr, abh. von Größe, Lokalisation, Geometrie

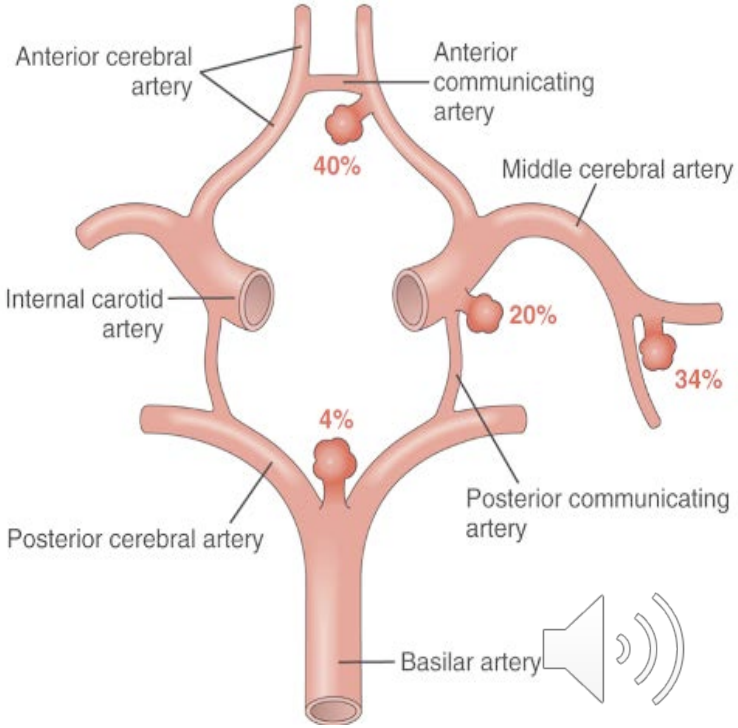

Coiling

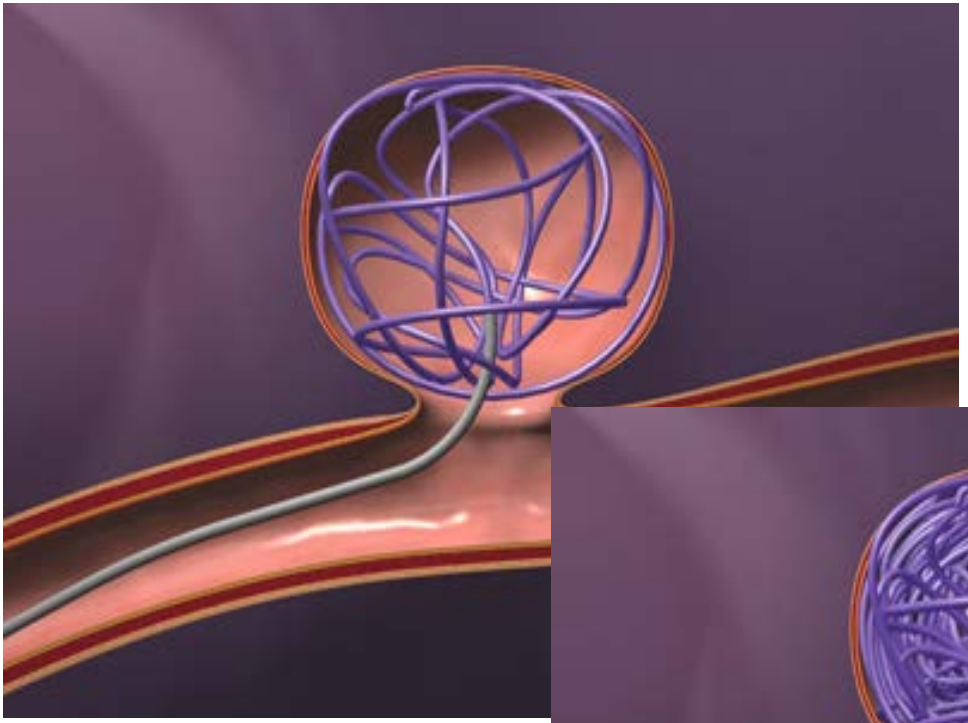

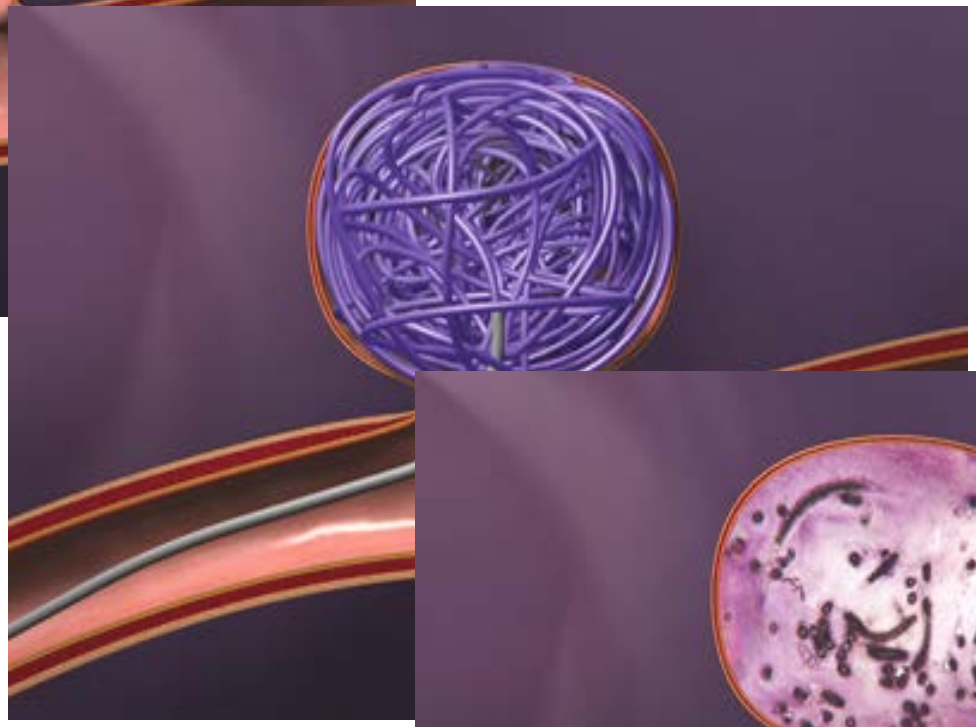

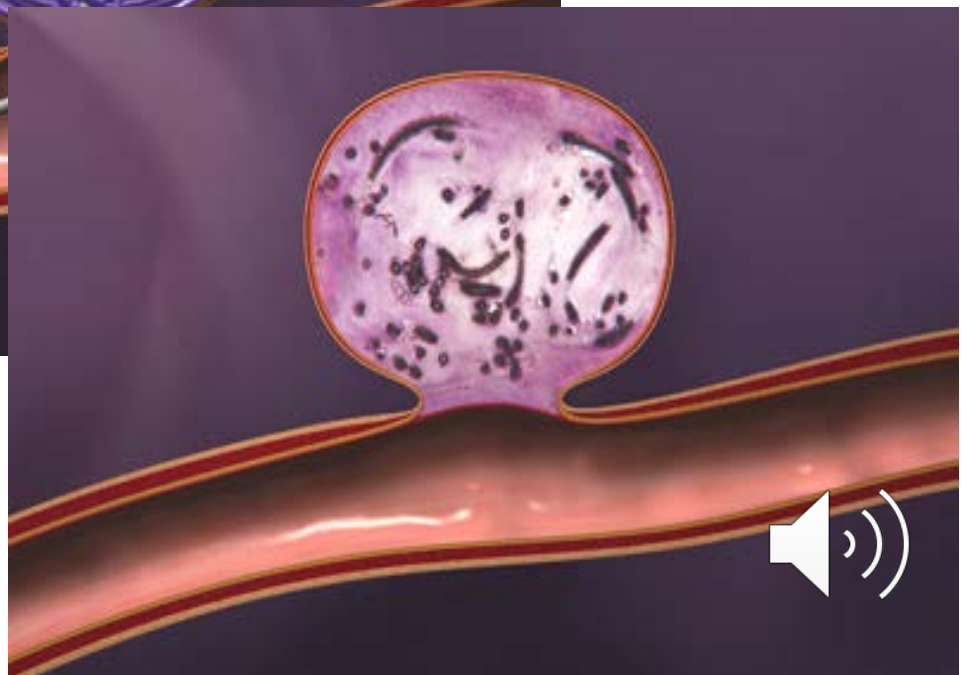

.....im echten Leben

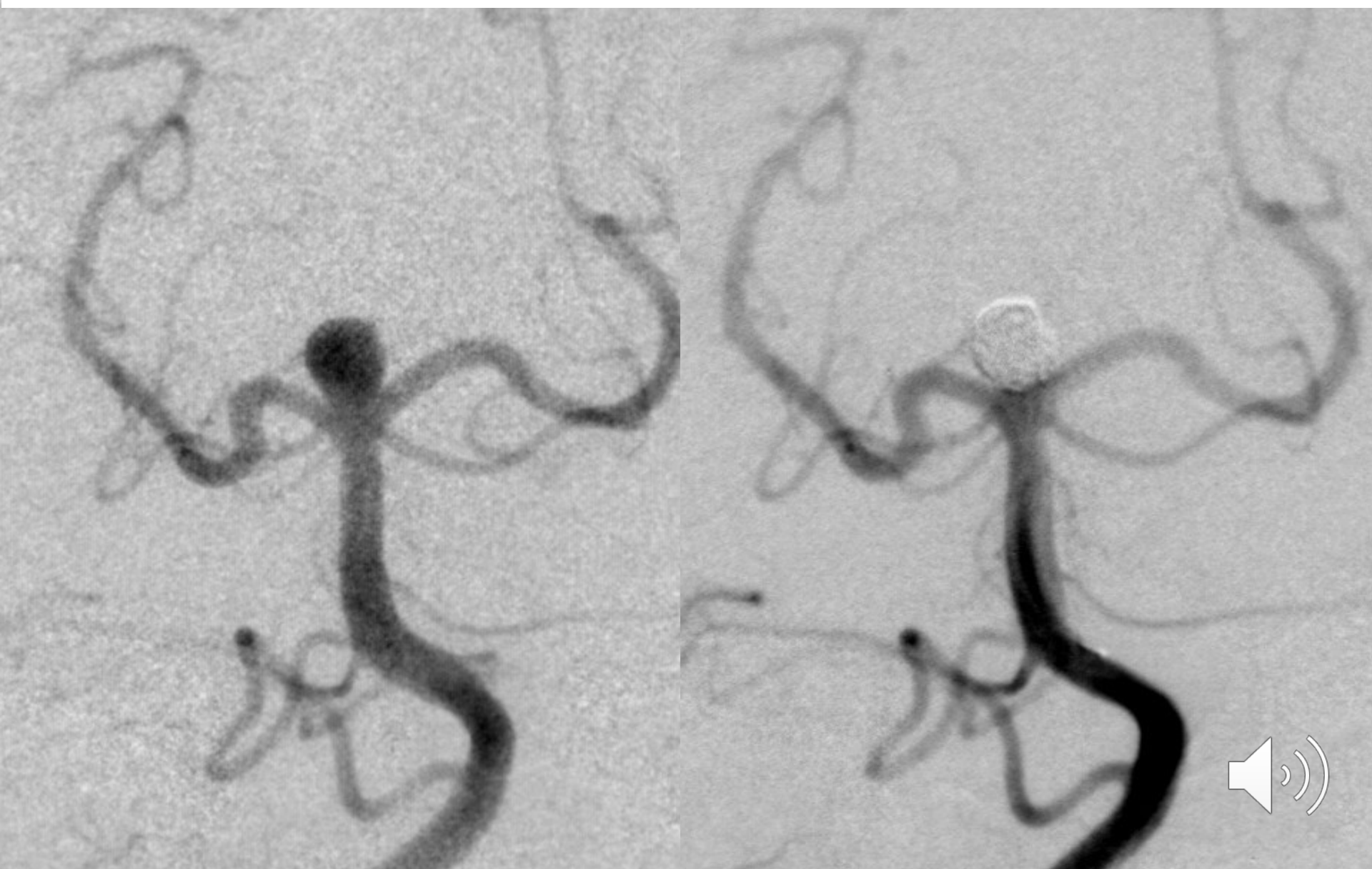

Coiling allein funktioniert leider nicht bei allen Aneurysmen....

Problem 2: Fusiforme Aneurysmen

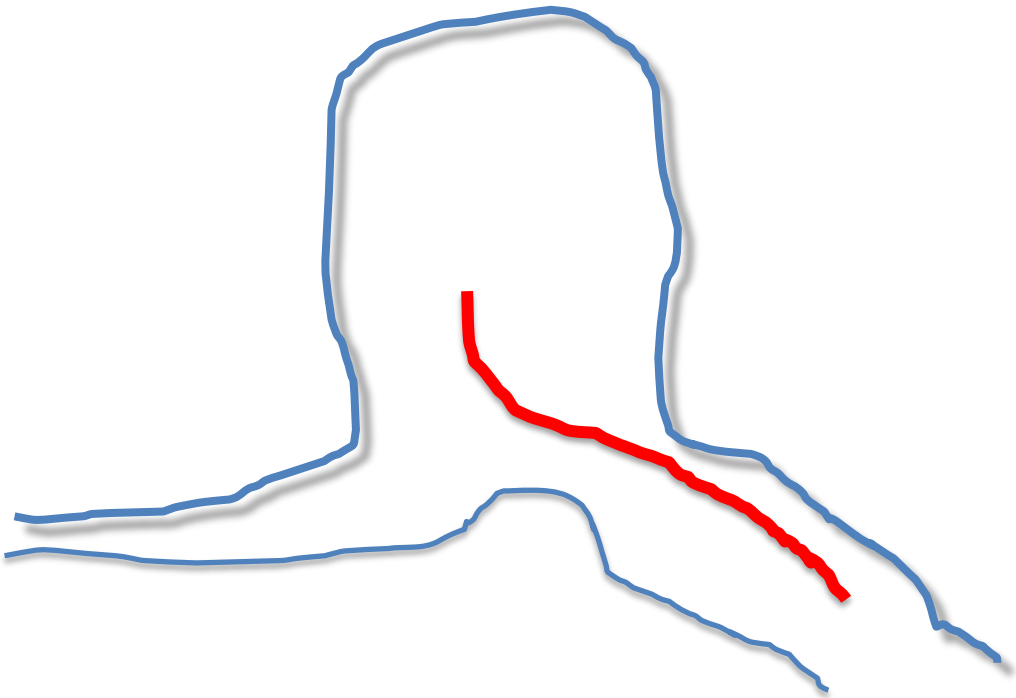

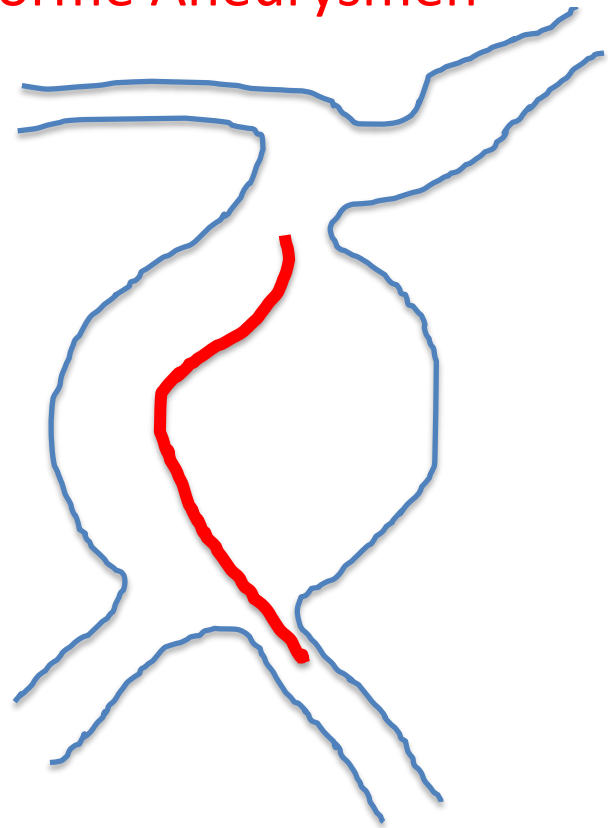

Problem 1: Breitbasige Aneurysmen

Ballonremodelling

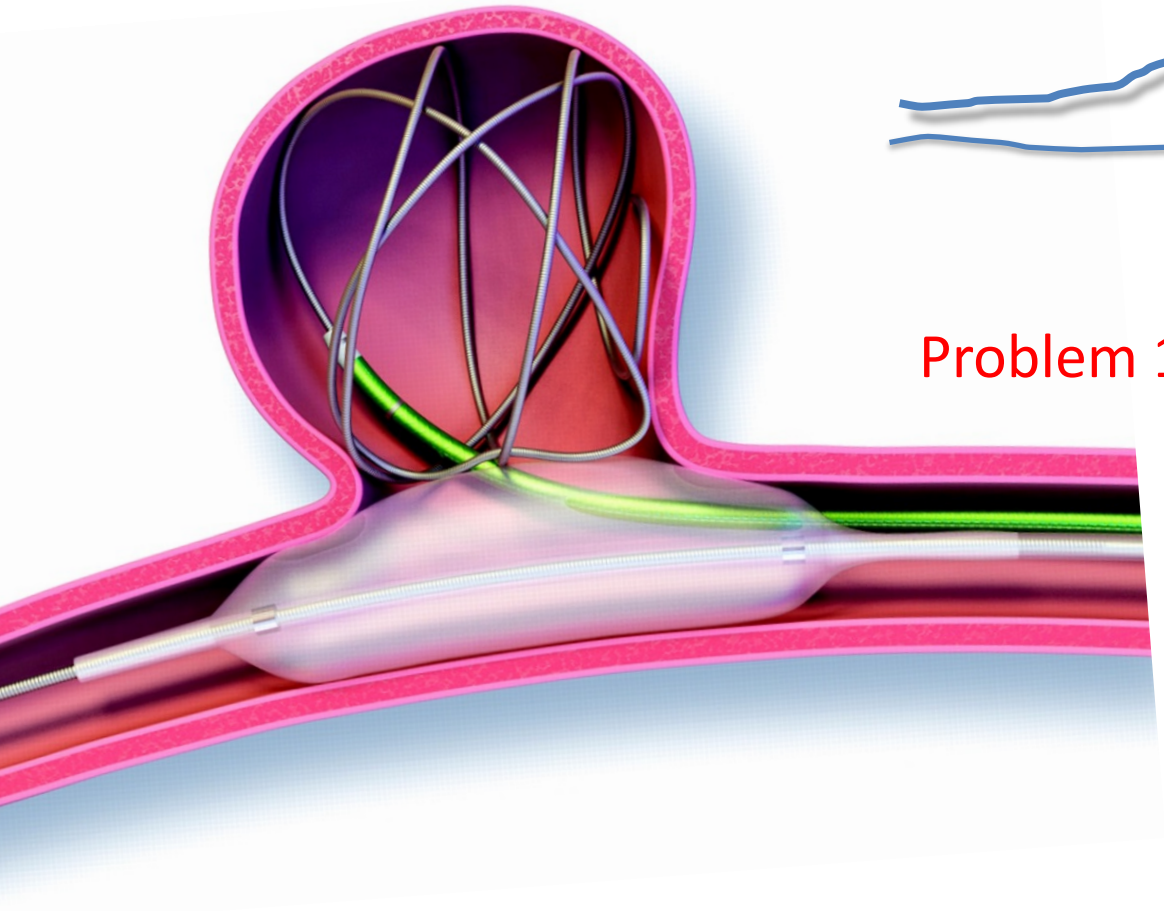

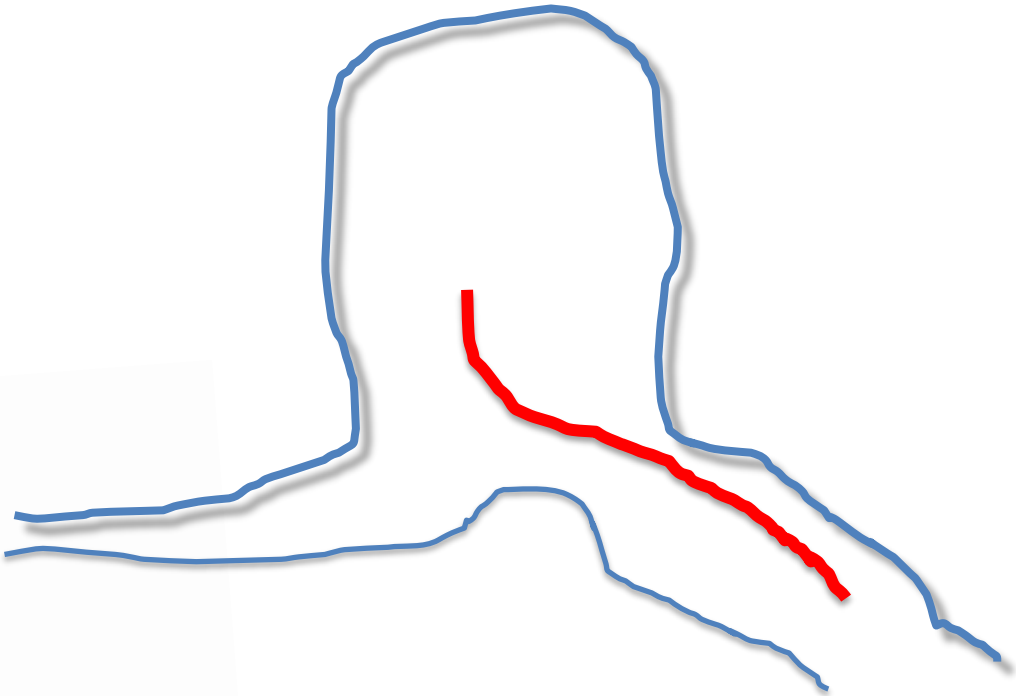

Problem 1: Breitbasige Aneurysmen

©2012 by American Society of Neuroradiology

L. Pierot et al. AJNR Am J Neuroradiol 2012;33:12-15

Ballonremodelling: Rezidiv eines gecoilten Pcom-Aneurysmas

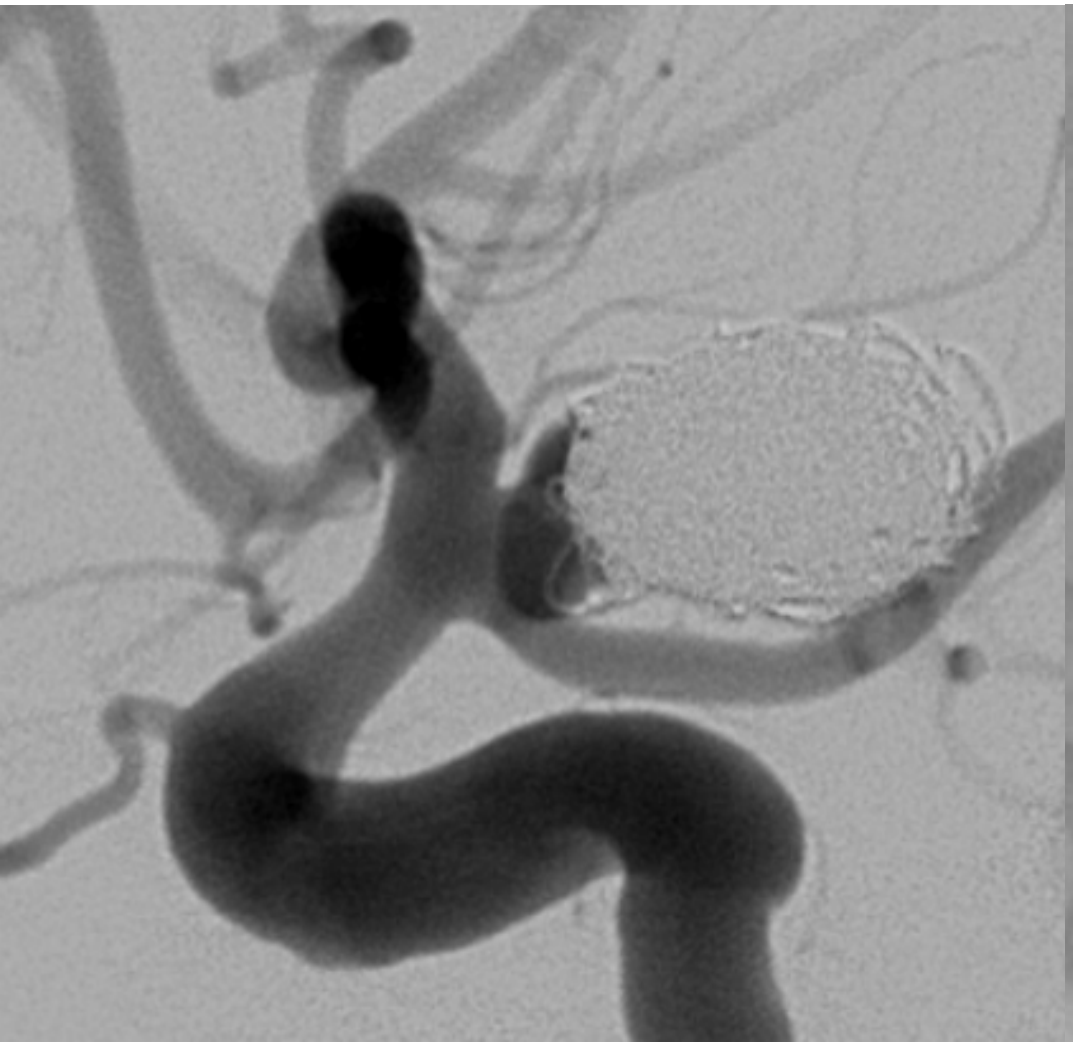

Ballonremodelling: Rezidiv eines gecoilten Pcom-Aneurysmas

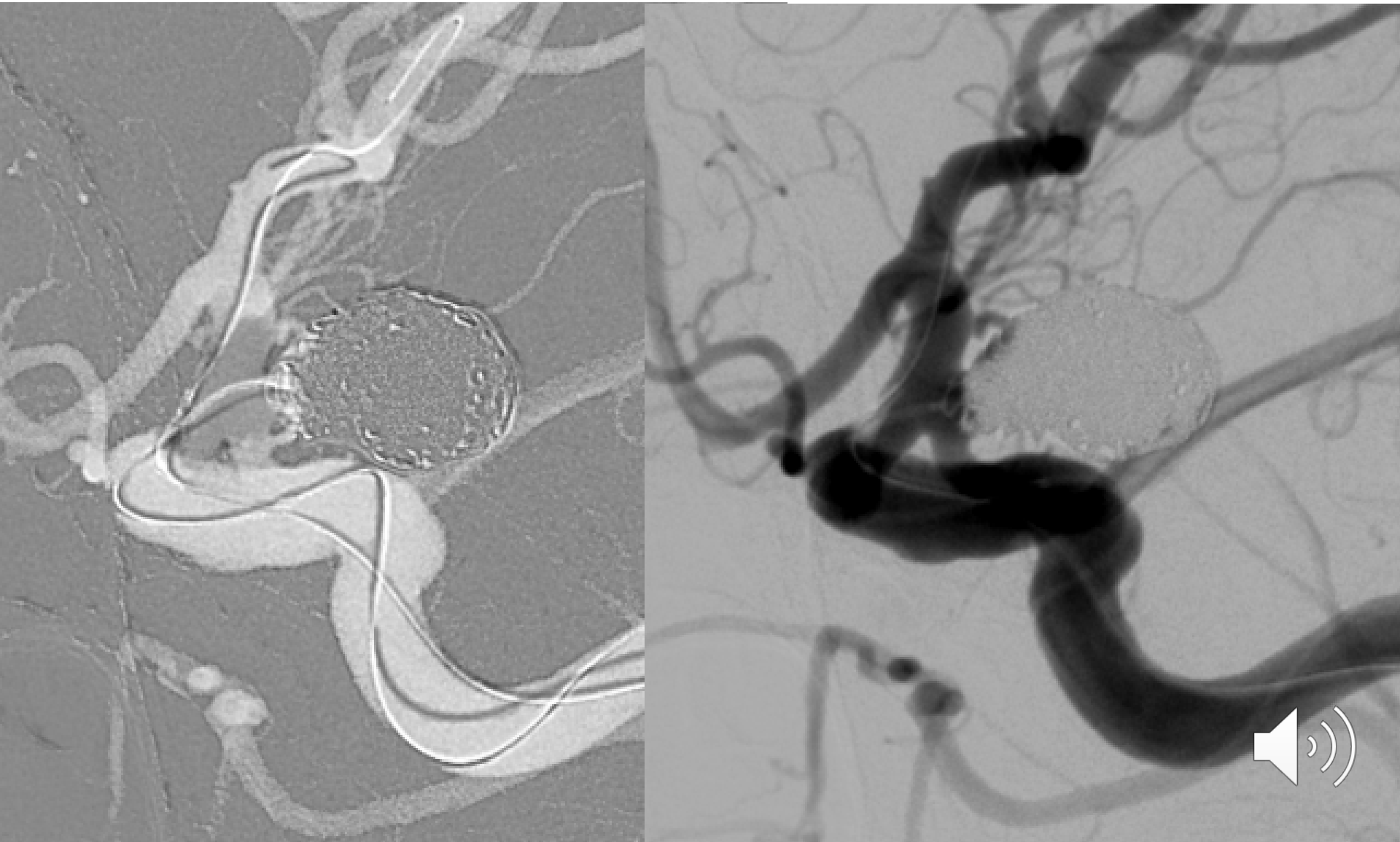

Stentassistiertes Coiling

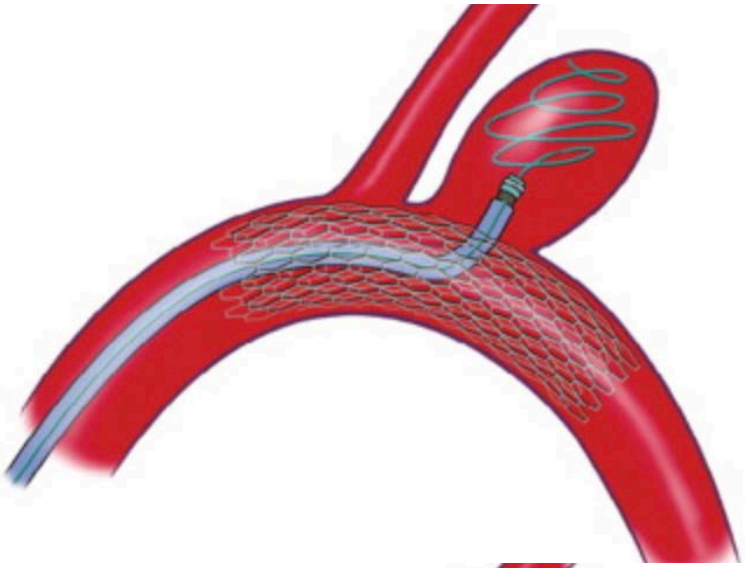

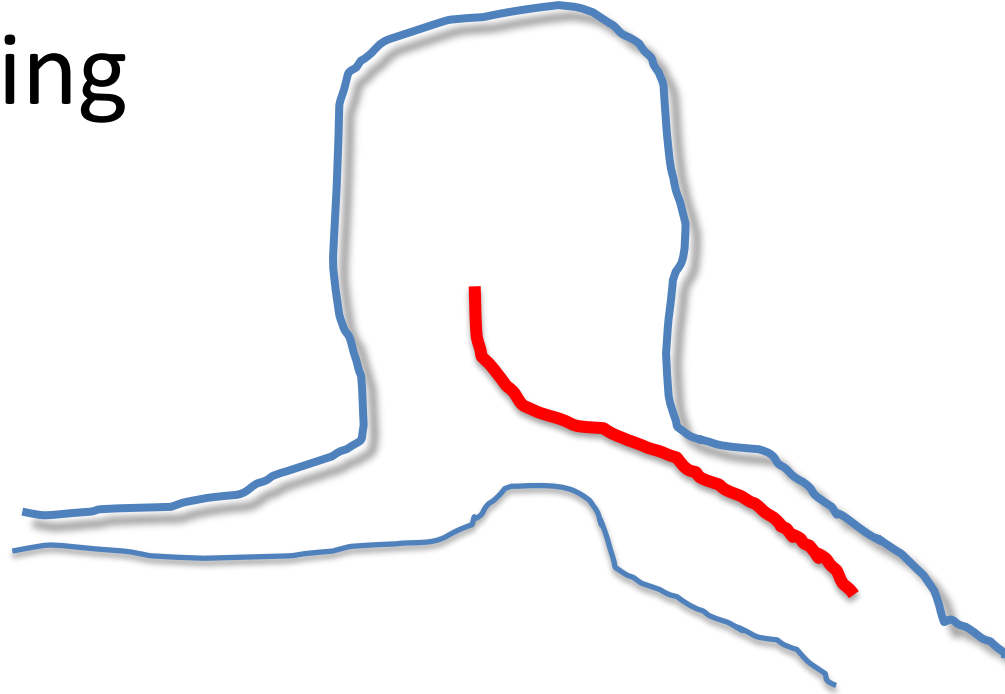

Problem 1: Breitbasige Aneurysmen

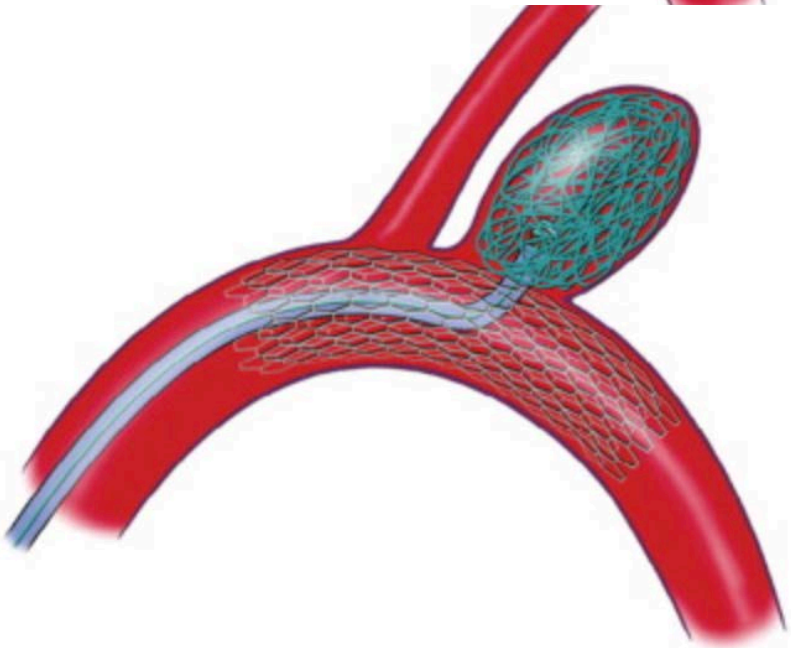

Stentassistiertes Coiling. Rupturiertes breitbasiges BA-Aneurysma

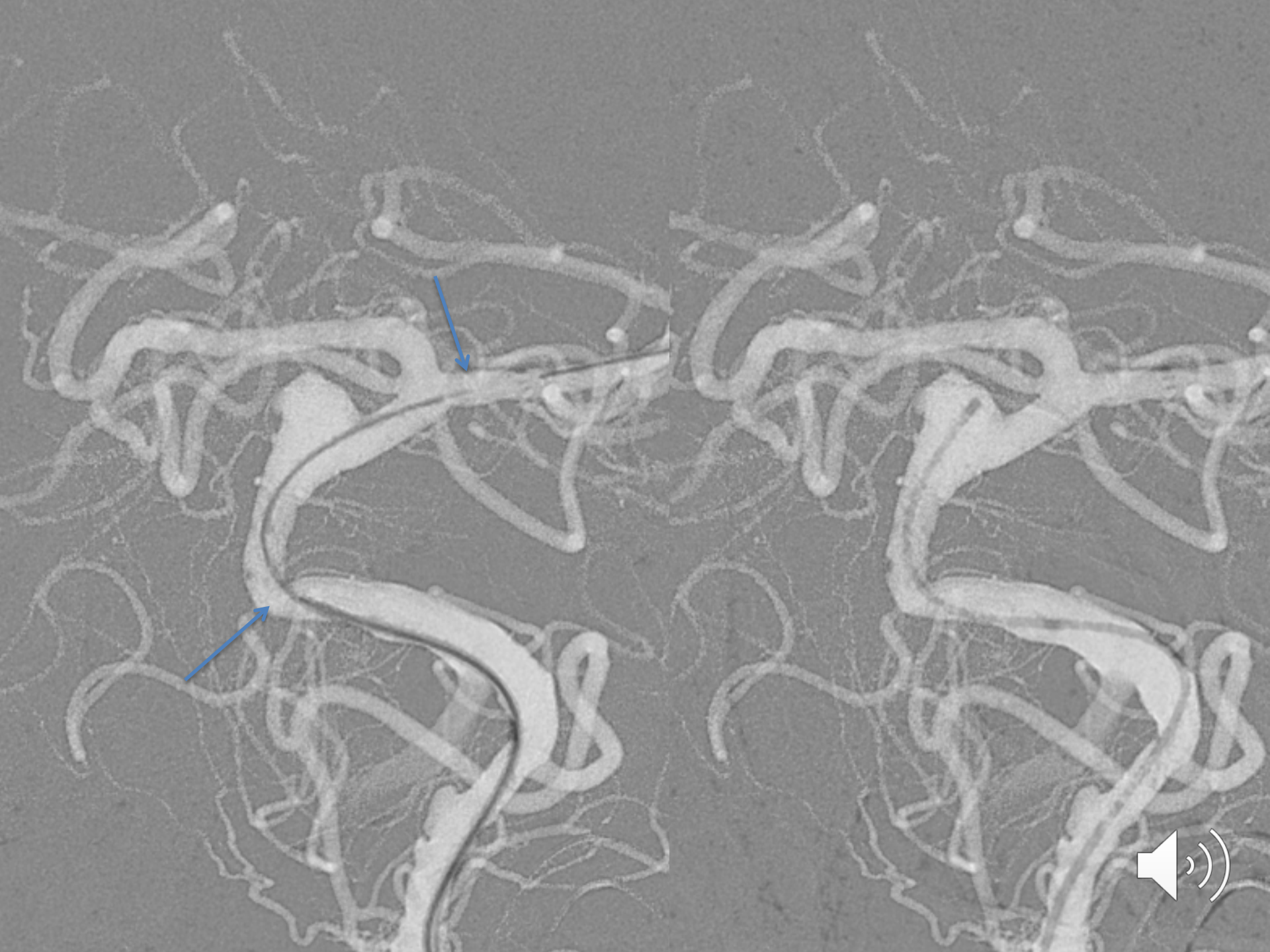

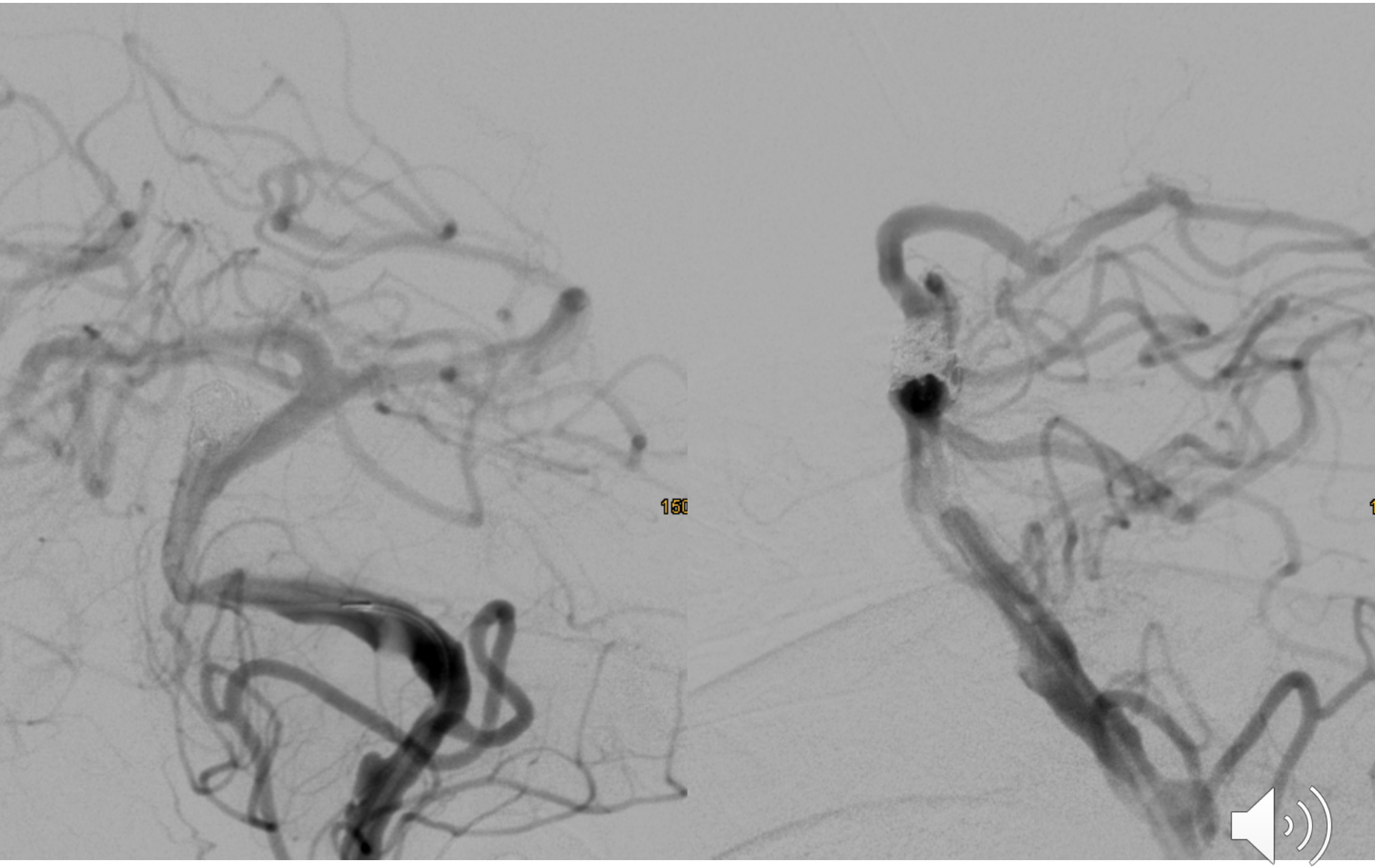
150

Fusiforme Aneurysmen ???

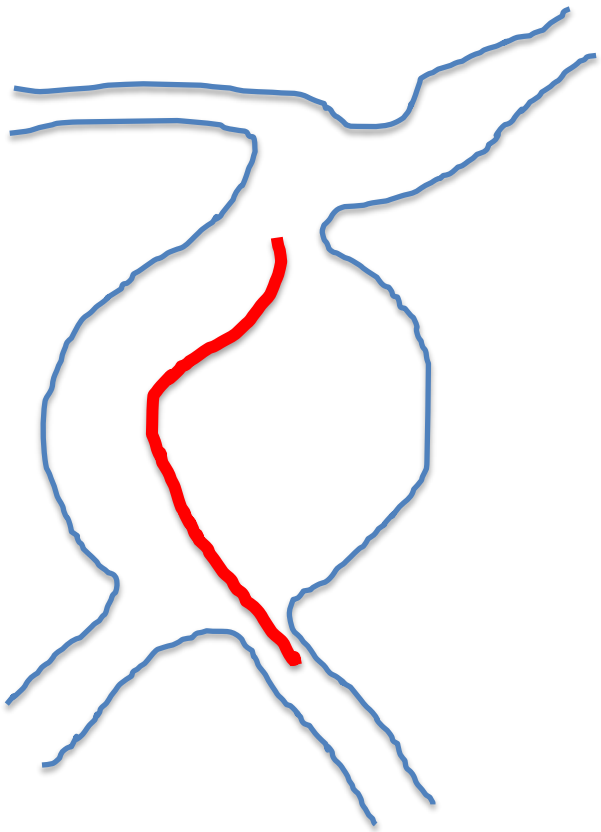

Idee: extrasakkuläre Behandlung

Barriere zwischen Trägergefäß und Aneurysma

CAVE: Perforatorverschlüsse!!

Flow Diverter: Flussmodellierung statt Entkoppelung

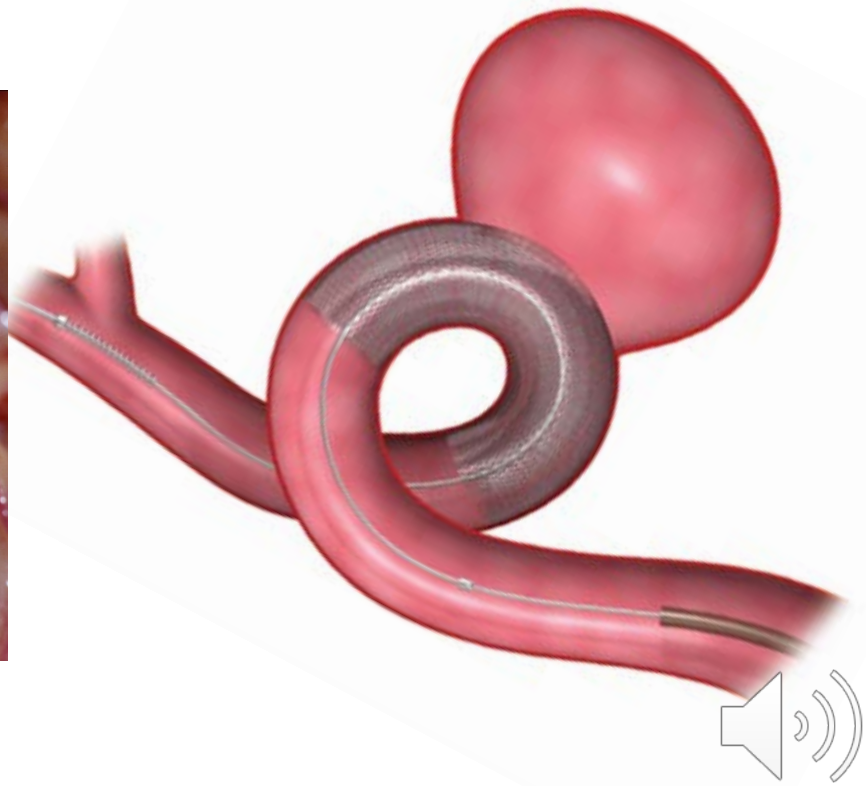

Fusiforme Aneurysmen: Flow Diverter



67J, akute Augenbewegungsstörung

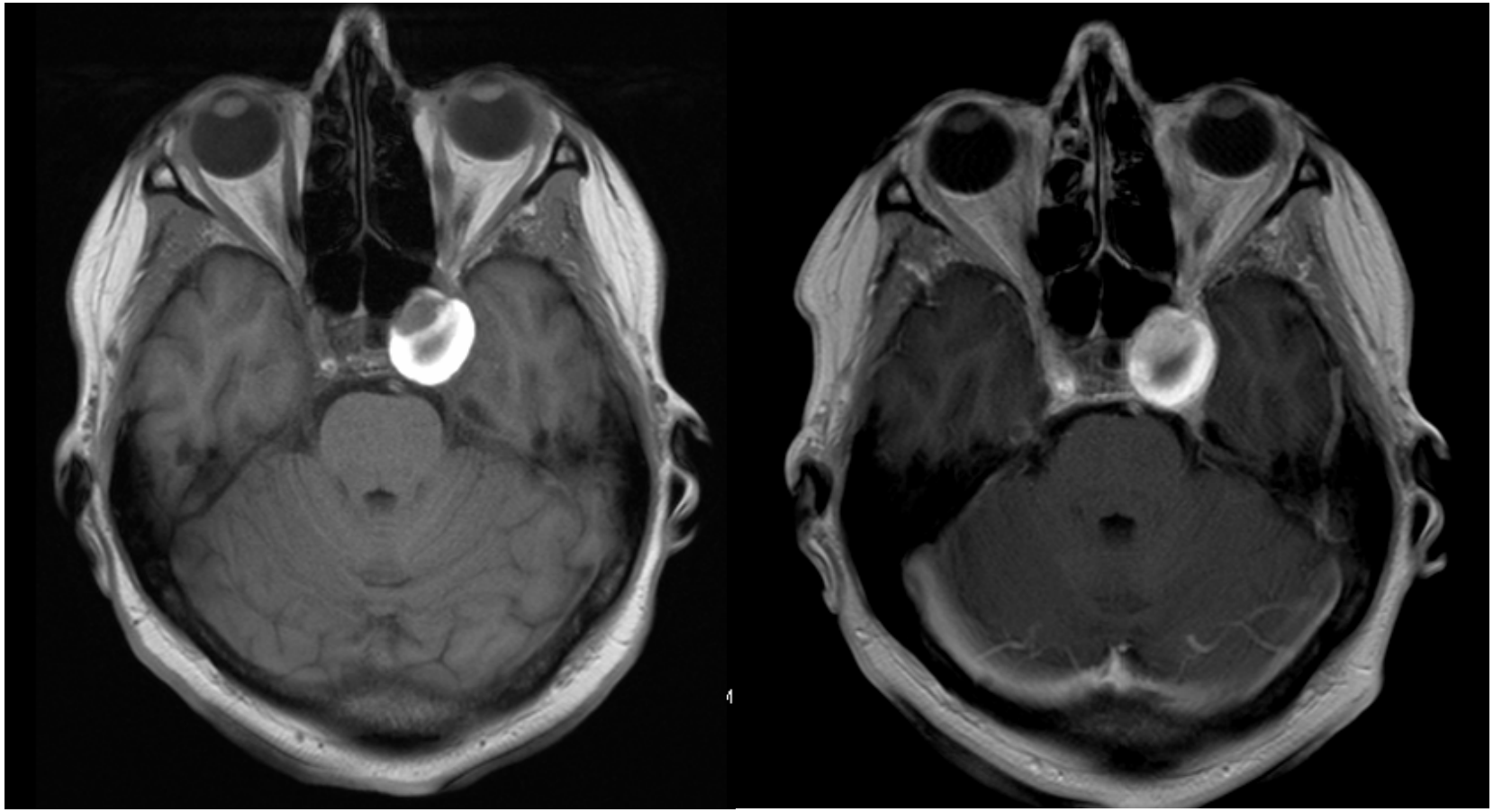

Fusiformes extraduales ACI-Riesenaneurysma, teilthrombosiert

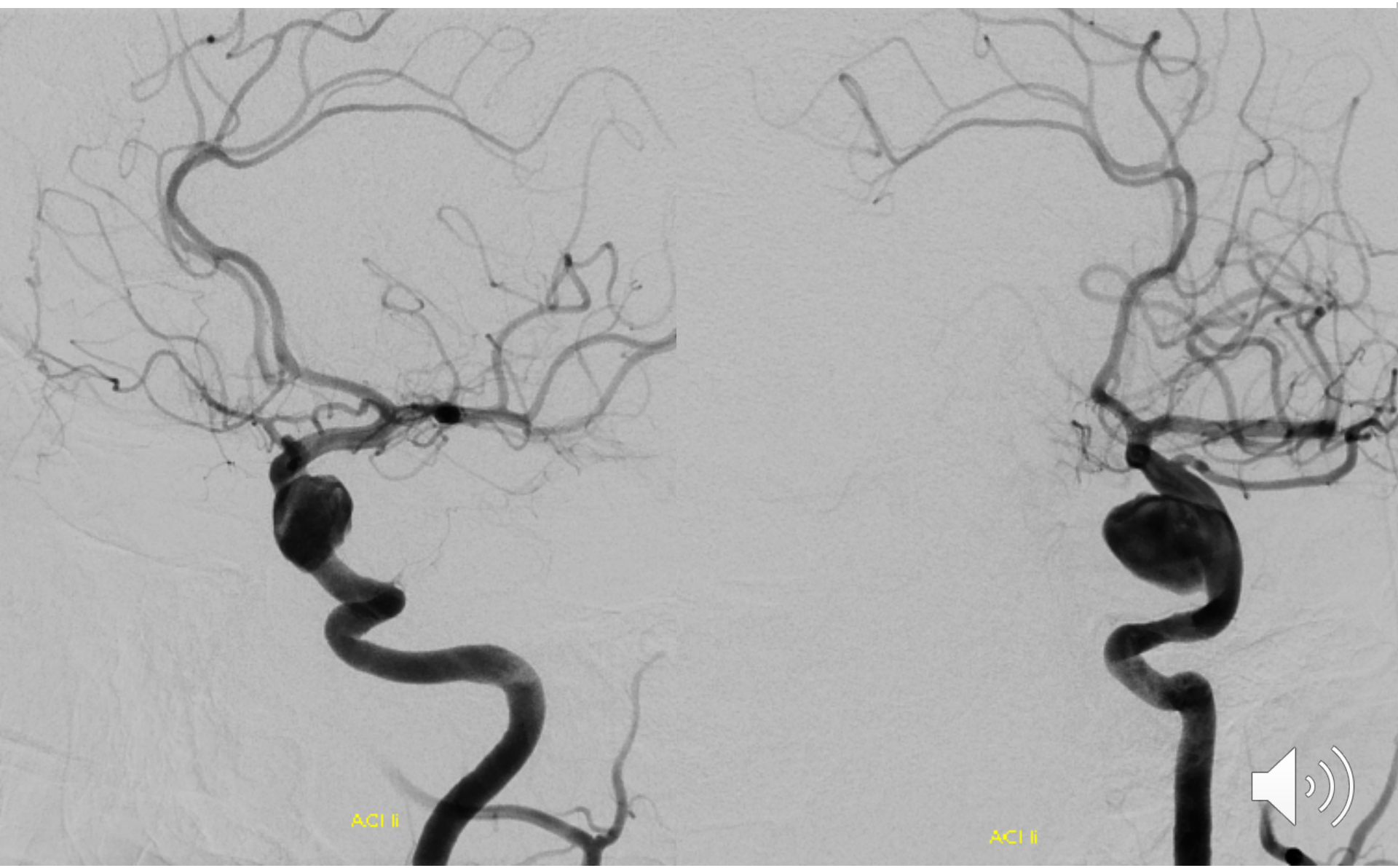

Freisetzen eines *Pipeline* (Medtronic) Flow Diverters über dem Aneurysmahals

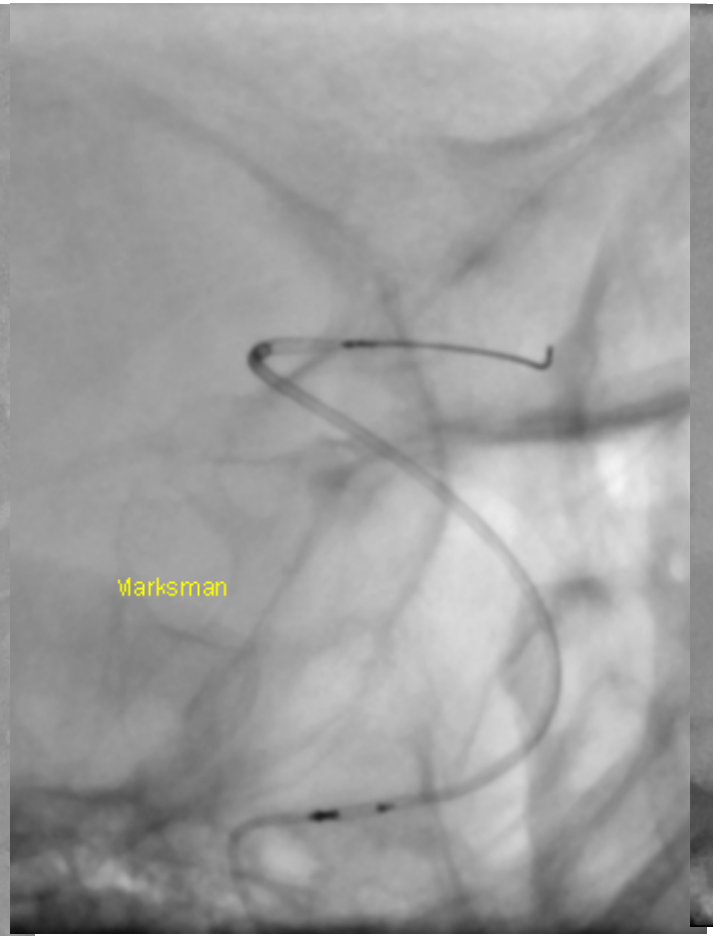

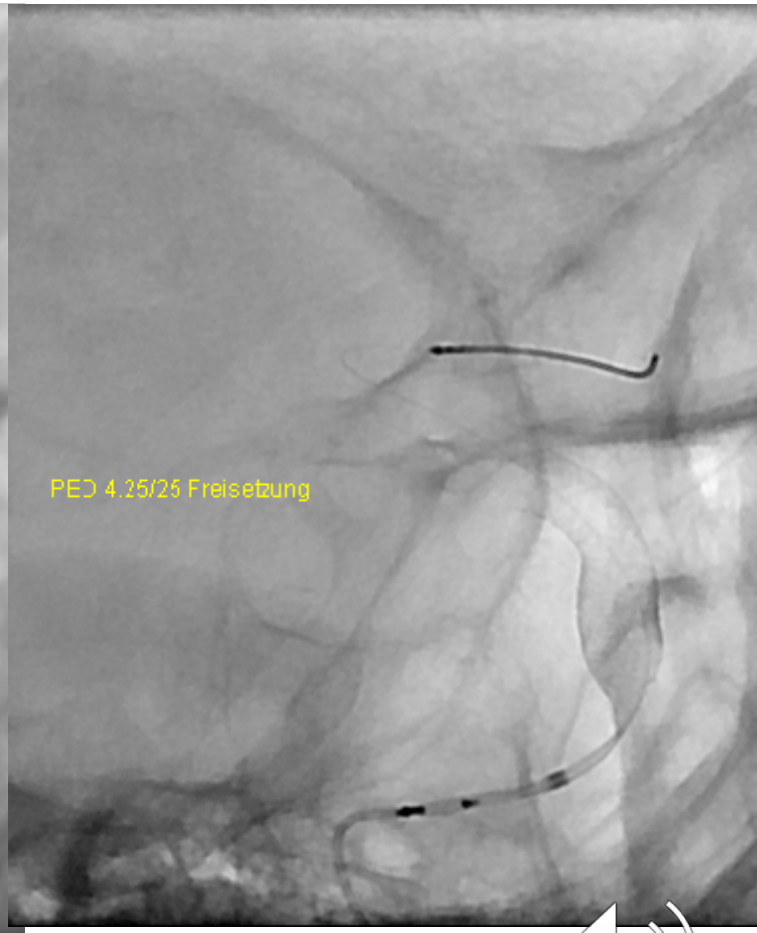

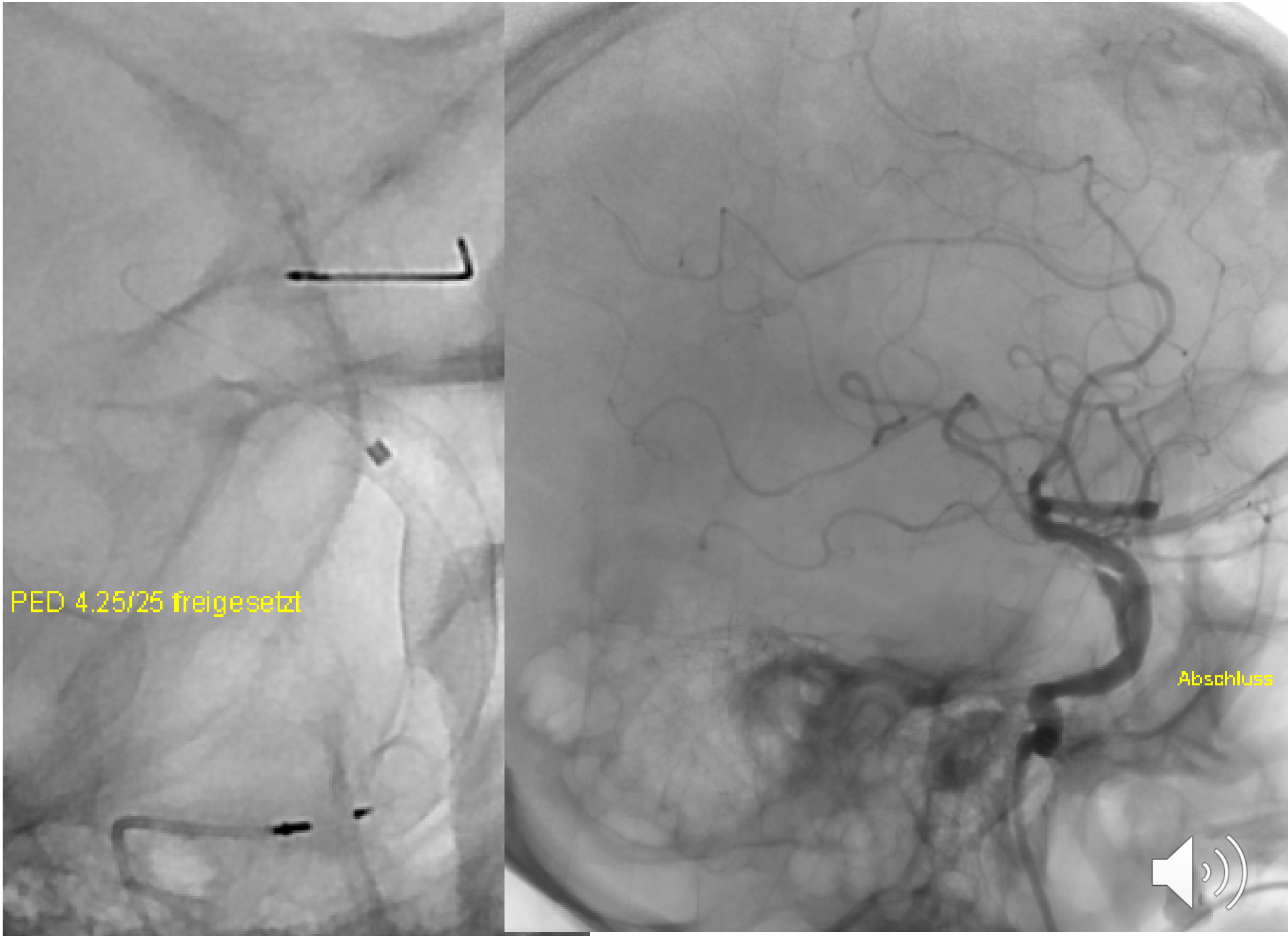
PED 4.25/25 freigesetzt
Abschluss

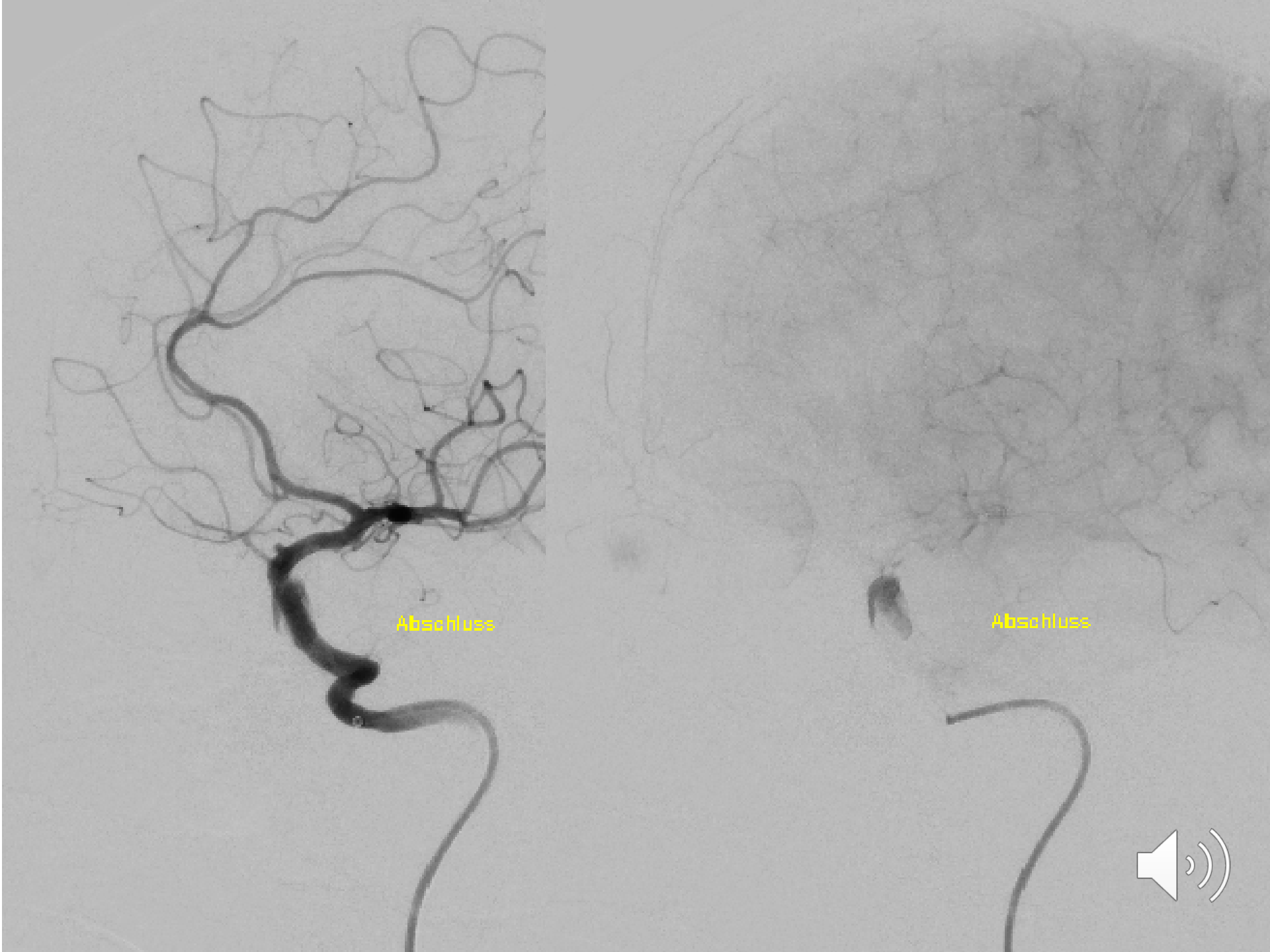
Abschluss
Abschluss

06/2016: MRT→ zunehmende Thrombosierung, klinisch deutlich gebessert

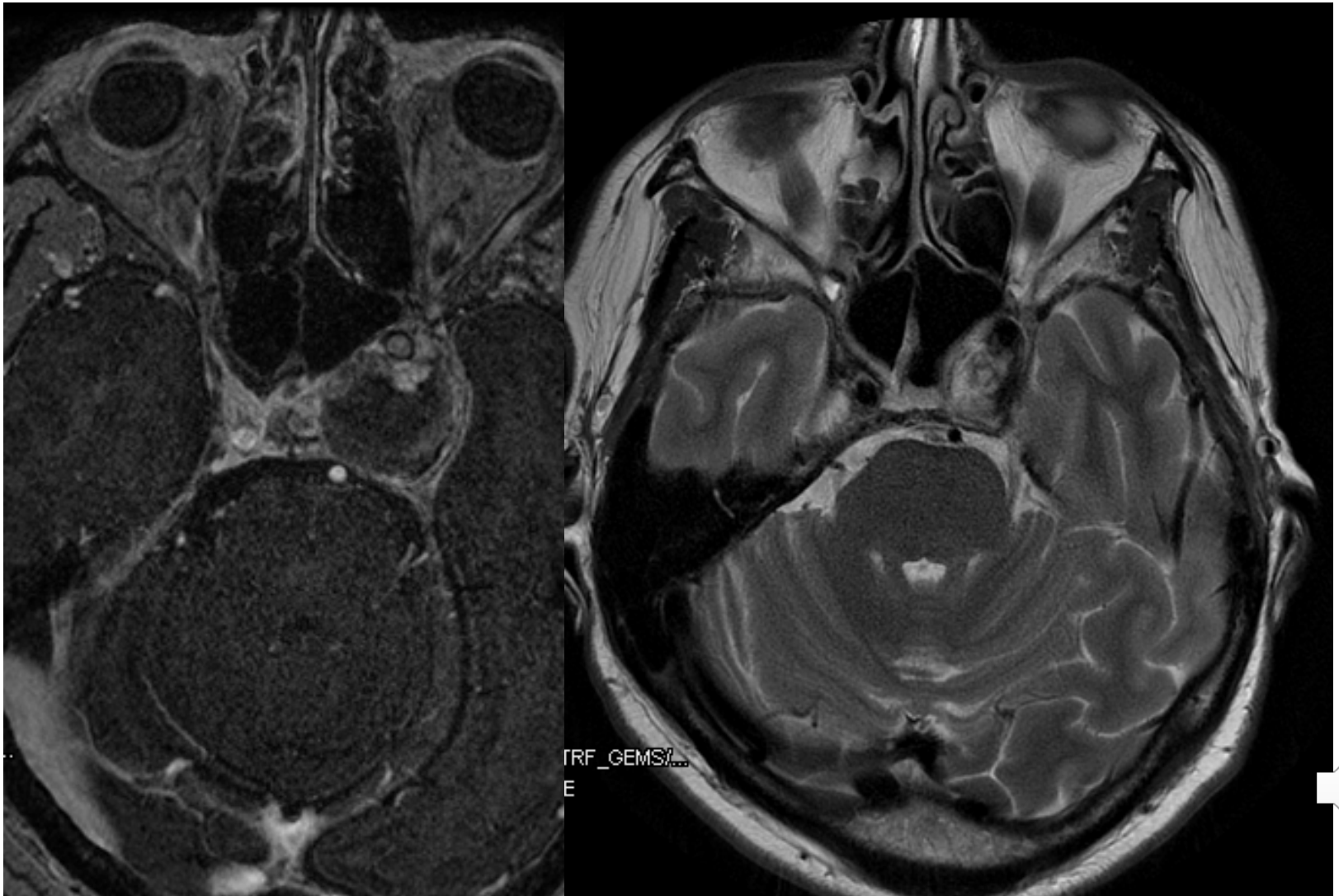

DSA 10/2016: Aneurysma (fast) komplett verschlossen, klinisch symptomfrei

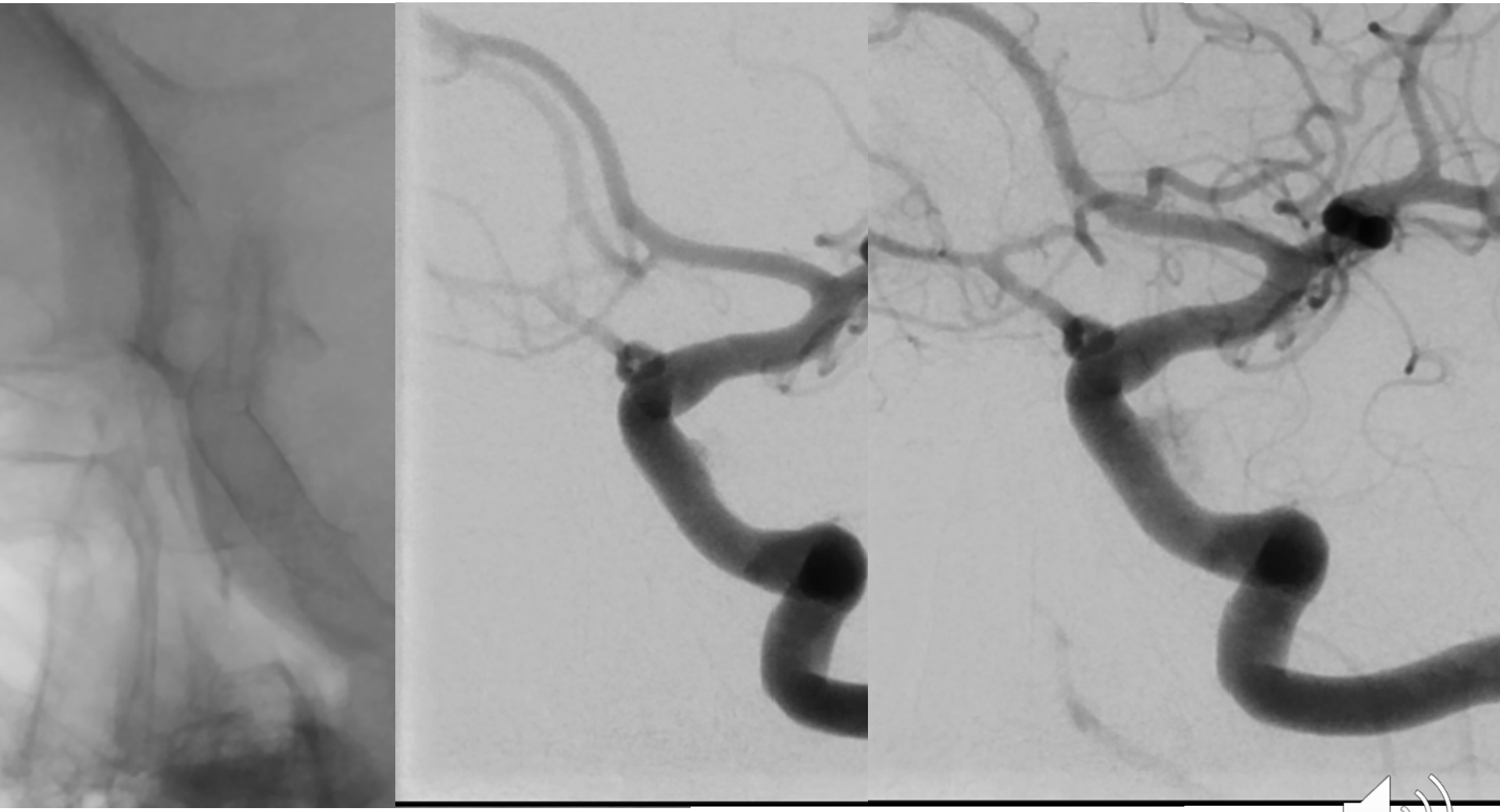

04/16: SAB, Dissektion der linken A. vertebralis

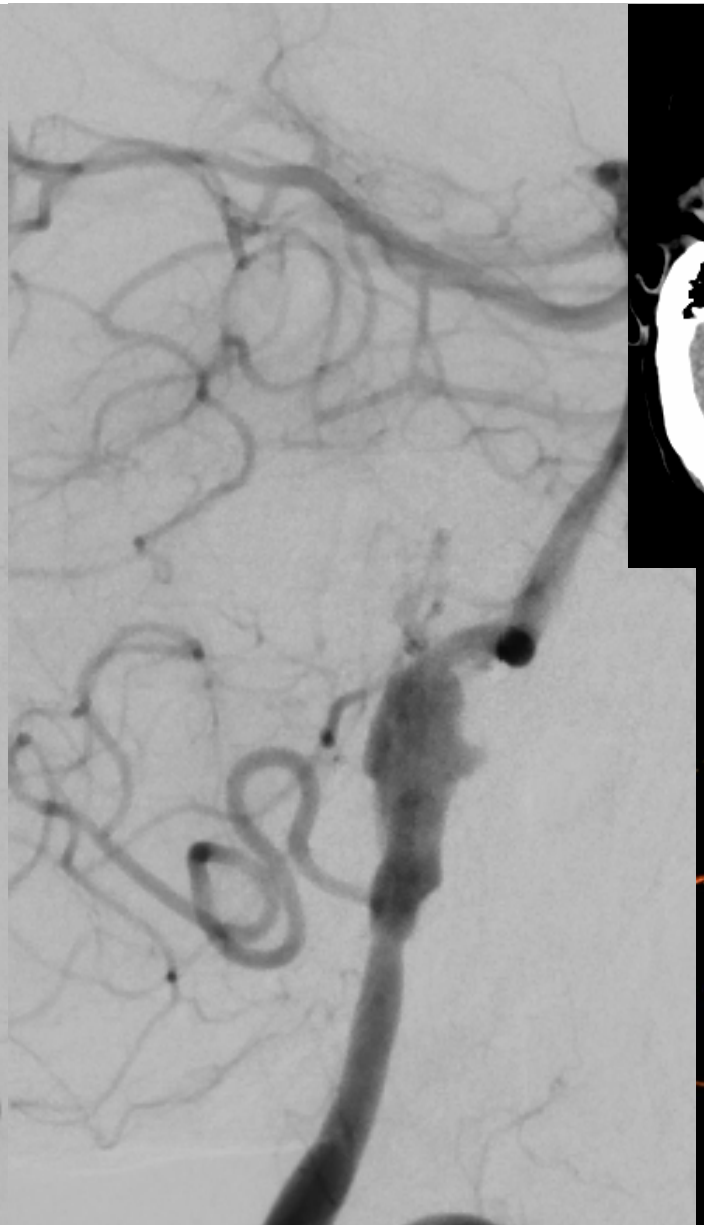

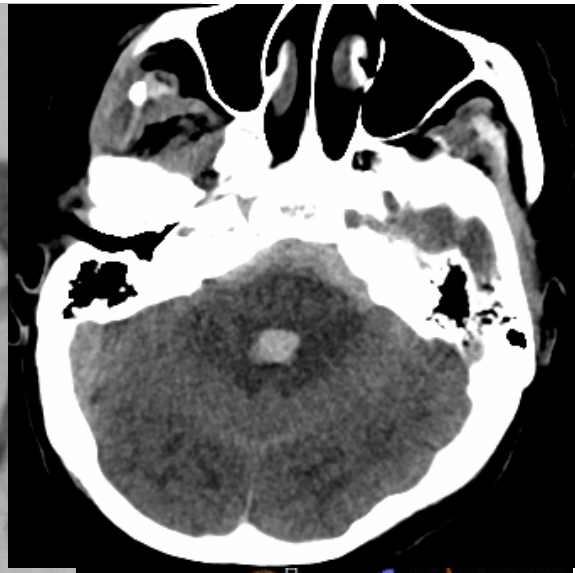

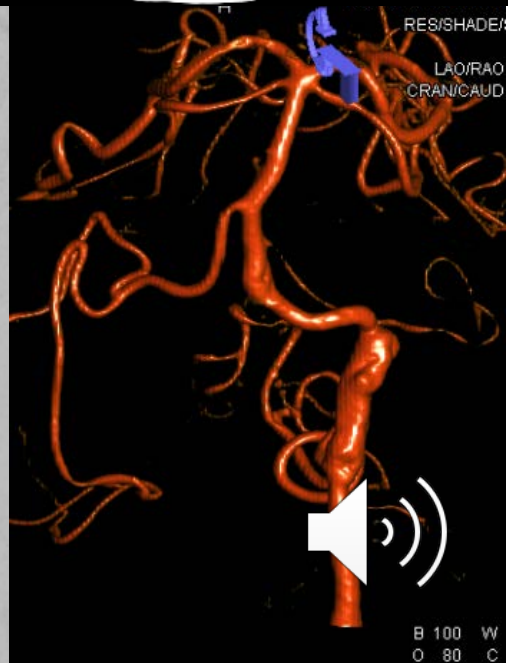

Überlappende Implantation von 3 Pipelines

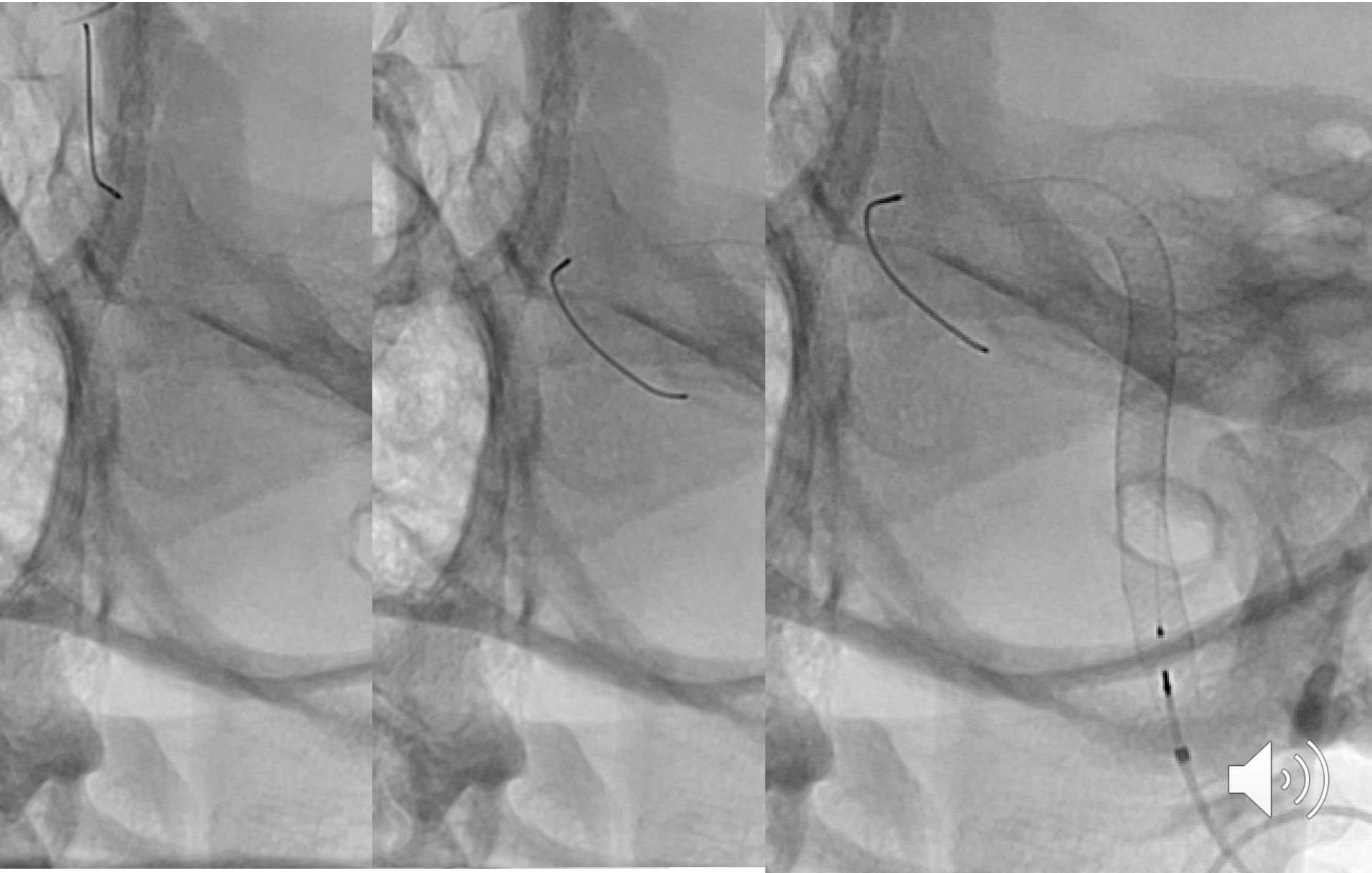

Abschluss/ nach 3 Wochen

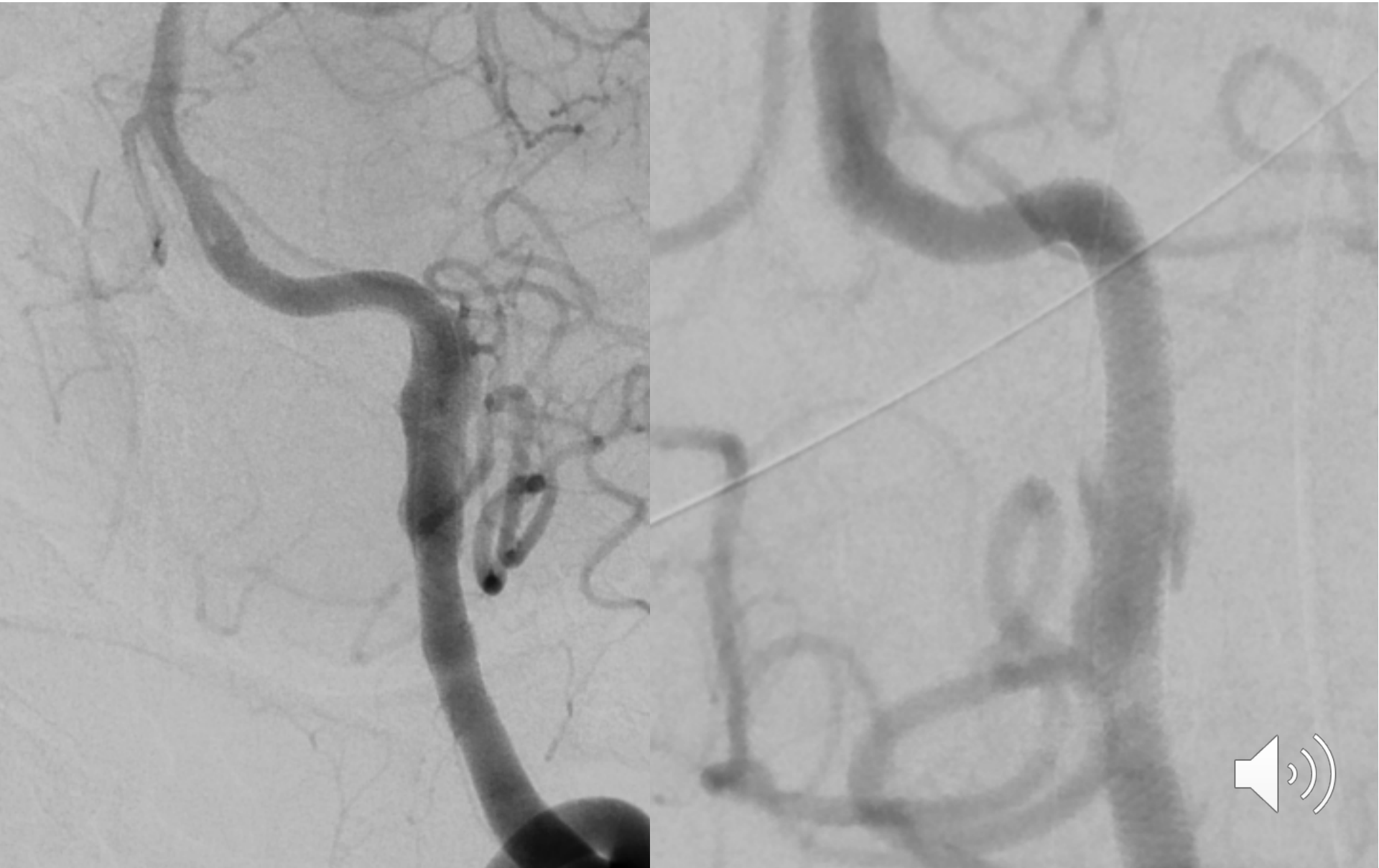

Kontrolle 09/2016

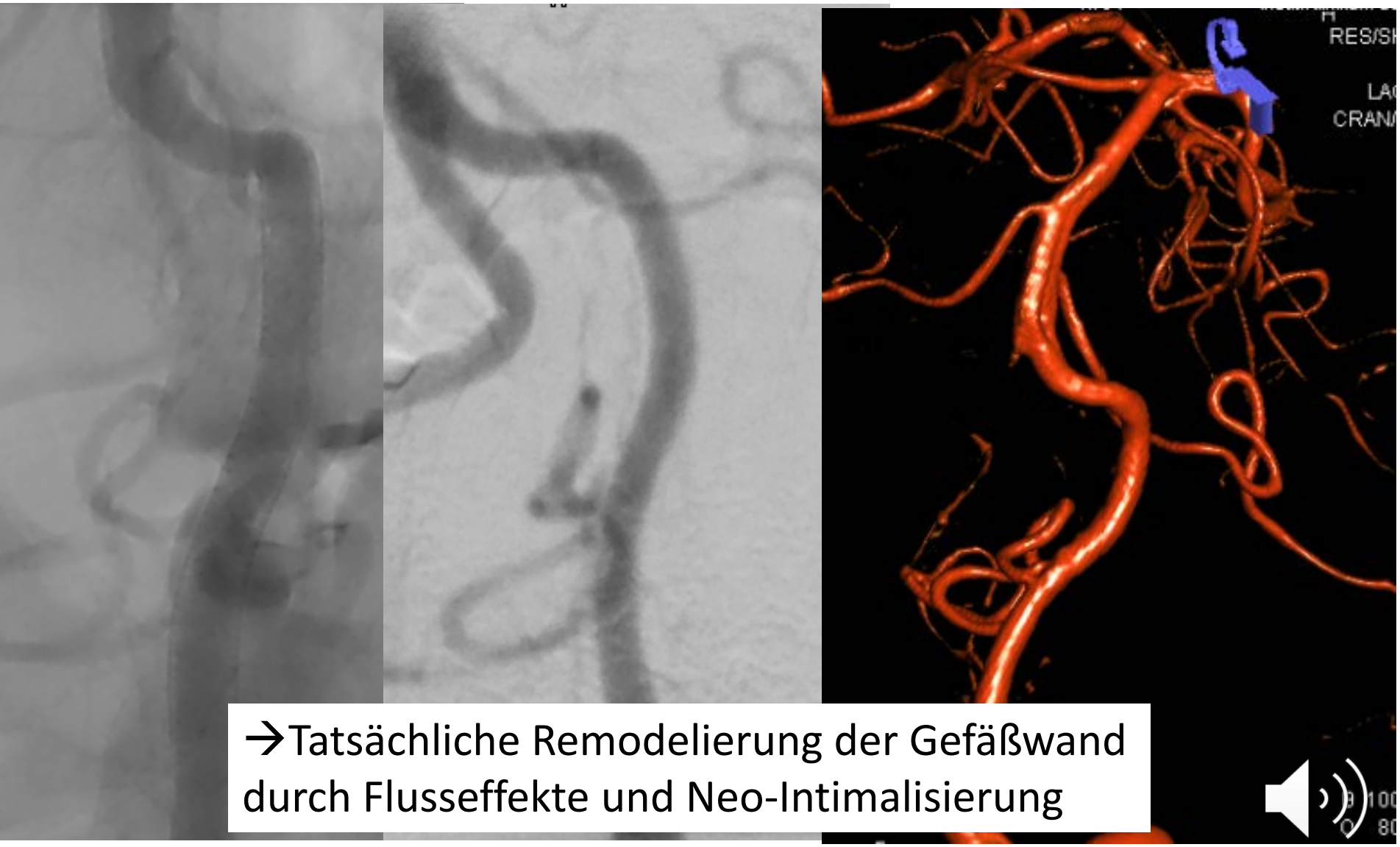

→Tatsächliche Remodelierung der Gefäßwand durch Flusseffekte und Neo-Intimalisierung

Relativ neu: Intraaneurysmale Flow Doverter: WEB (Sequent)



WEB: Inzidentelles BA-Aneurysma

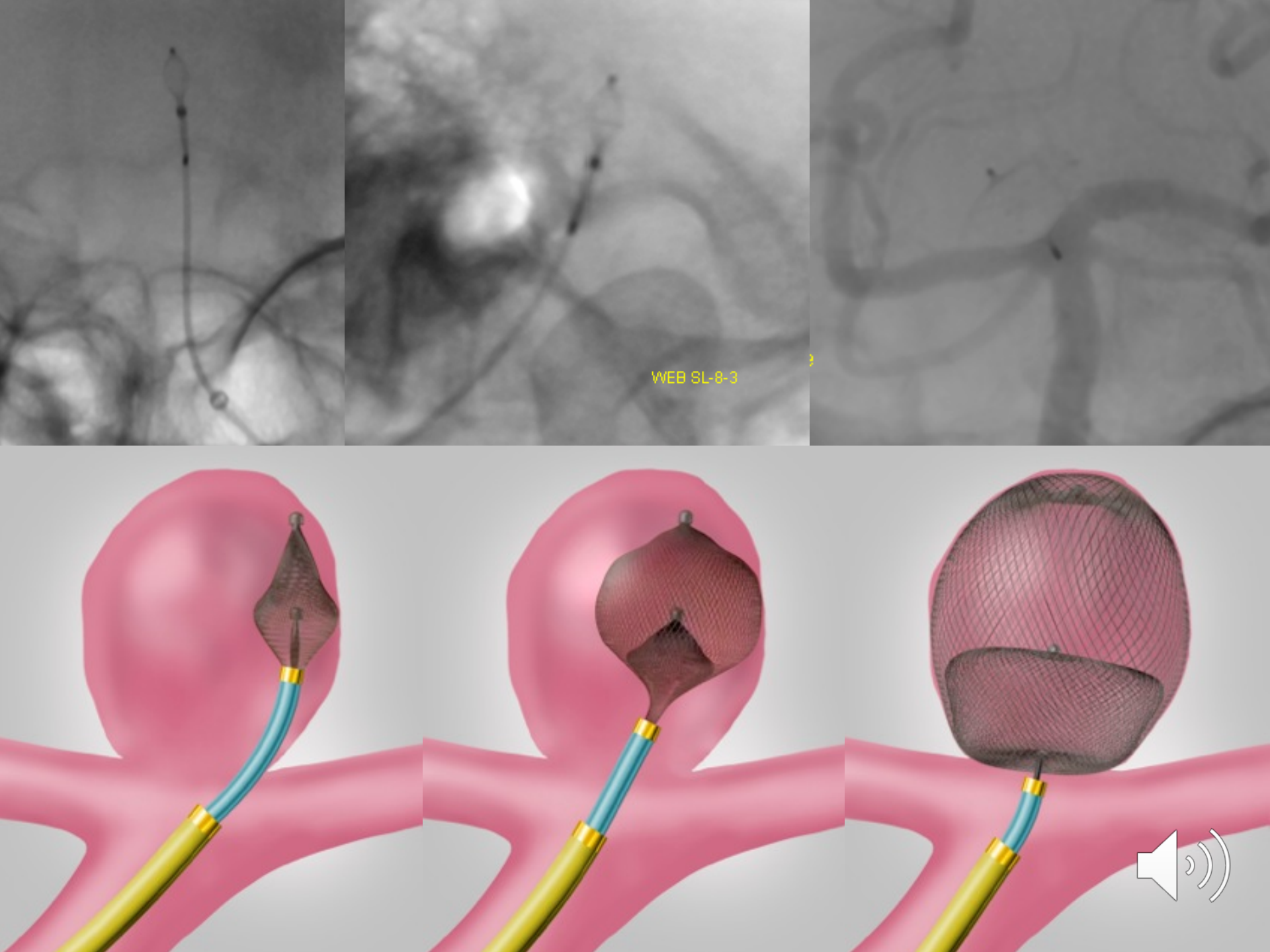
WEB SL-8-3

Abschlusskontrolle

Akute Schlaganfallbehandlung: Thrombektomie

160–240 Ereignisse/100.000 Einwohner
Häufigste Ursache für Langzeitbehinderung

Stroke
JOURNAL OF THE AMERICAN HEART ASSOCIATION

NIHSS Score and Arteriographic Findings in Acute Ischemic Stroke

Urs Fischer, Marcel Arnold, Krassen Nedeltchev, Caspar Brekenfeld, Pietro Ballinari, Luca Remonda, Gerhard Schroth and Heinrich P. Mattle

Stroke 2005;36;2121-2125; originally published online Sep 8, 2005;
DOI: 10.1161/01.STR.0000182099.04994.fc
Stroke is published by the American Heart Association. 7272 Greenville Avenue, Dallas, TX 72514
Copyright © 2005 American Heart Association. All rights reserved.
Print ISSN: 0039-2499. Online ISSN: 1524-4628

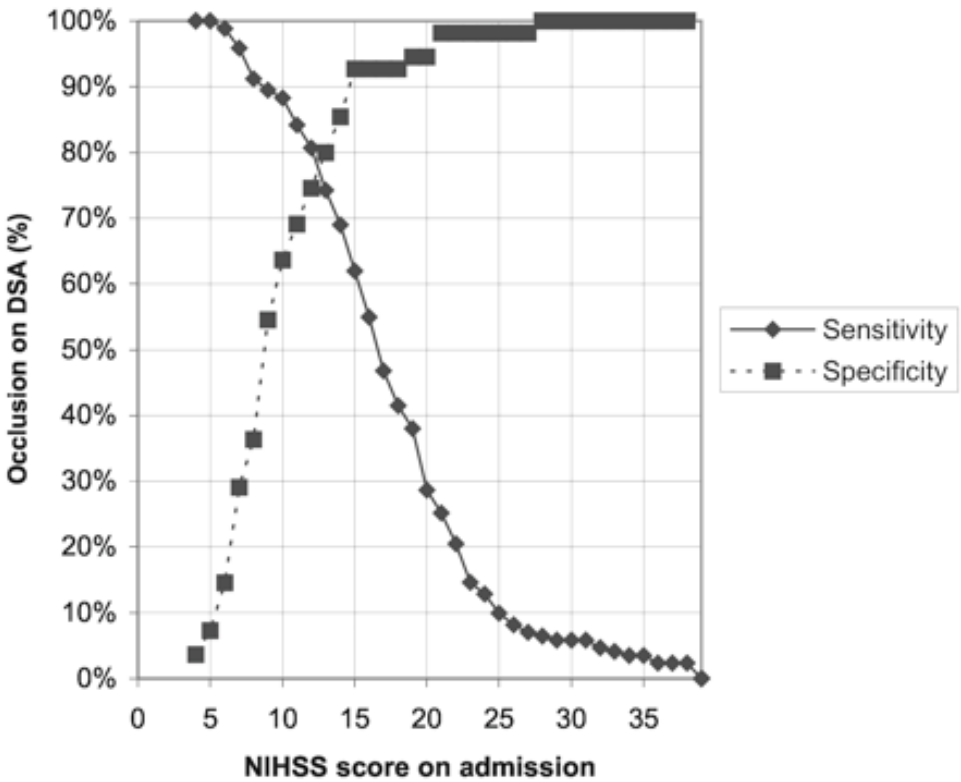

- NIHSS ≥12 → fast immer Hauptstammverschluss (PPV = 91%)

ABER:

- Patienten mit Hauptstammverschlüssen profitieren in weniger als 10% von der systemischen/ IV Lyse

Lokale Lysetherapie

Lokale Fibrinolysetherapie bei Basilaris-Thrombose

H. Zeumer, W. Hacke, H. L. Kolmann und K. Poeck

Neurologische Klinik der medizinischen Einrichtungen der Rheinisch-Westfälischen Technischen Hochschule Aachen (Vorstand: Prof. Dr. K. Poeck)

Bei einer 27jährigen Patientin mit akutem Verschluß der A. basilaris war eine lokale Fibrinolysetherapie über einen in der A. vertebralis liegenden Katheter erfolgreich. Klinische, elektrophysiologische und radiologische Befunde ließen die rasche und eindrucksvolle Befundbesserung erkennen.

Local fibrinolysis in basilar artery thrombosis

Local fibrinolysis via a catheter in the vertebral artery was successfully performed in a 27-year-old female patient with acute occlusion of the basilar artery. Clinical, electrophysiological and radiographic data confirmed rapid and impressive improvement of findings.

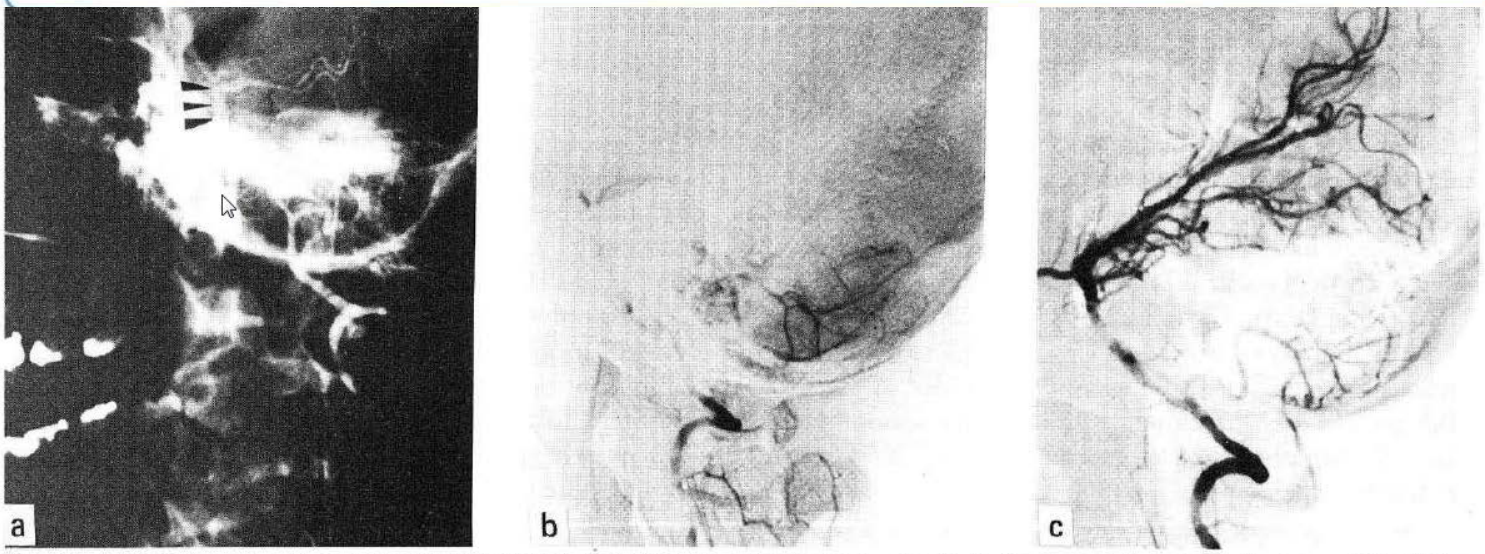

Abb. 2. a) Darstellung des Basilaristhrombus in Schrägprojektion über den in der A. vertebralis liegenden Perfusionskatheter. – b) Seitliche Aufnahme zu Abbildung 1a vor Therapiebeginn. – c) Seitliche Aufnahme zu Abbildung 1d nach Therapieende.

Mechanische Thrombektomie

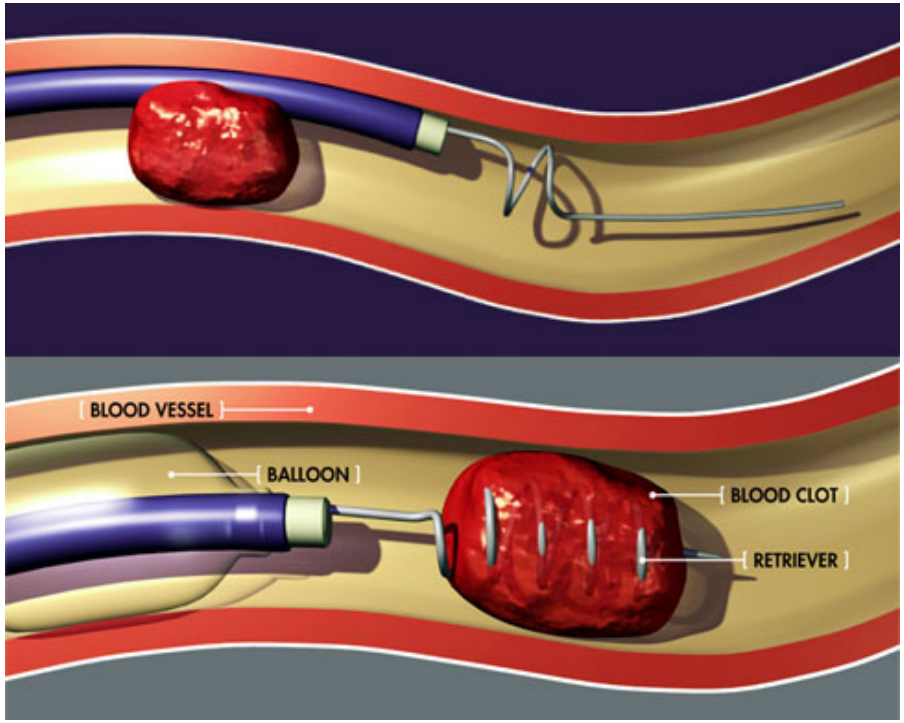

MERCI

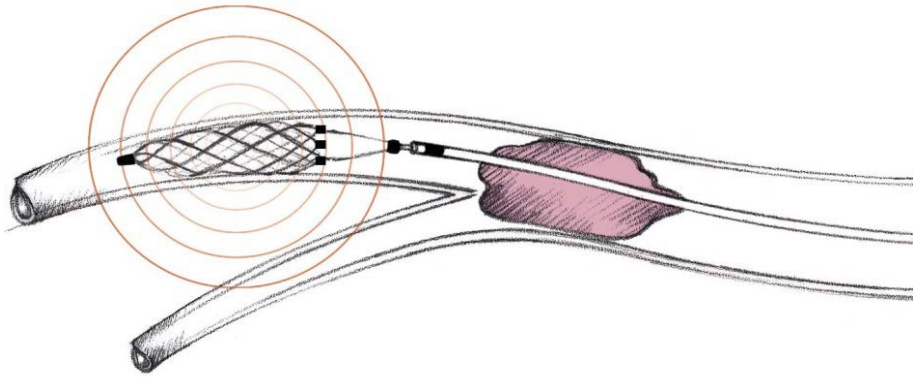

Catch

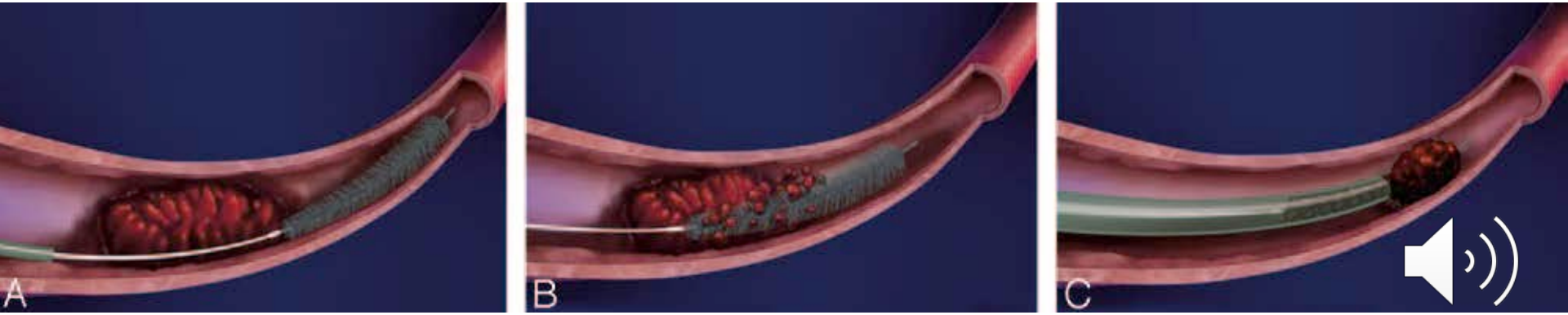

Phenox Cot Retriever

2008

30 Jahre, keine Vorerkrankungen
Halbseitenlähmung links seit 16.30 Uhr
Aufnahme 17.05, CCT 17.15 UHR

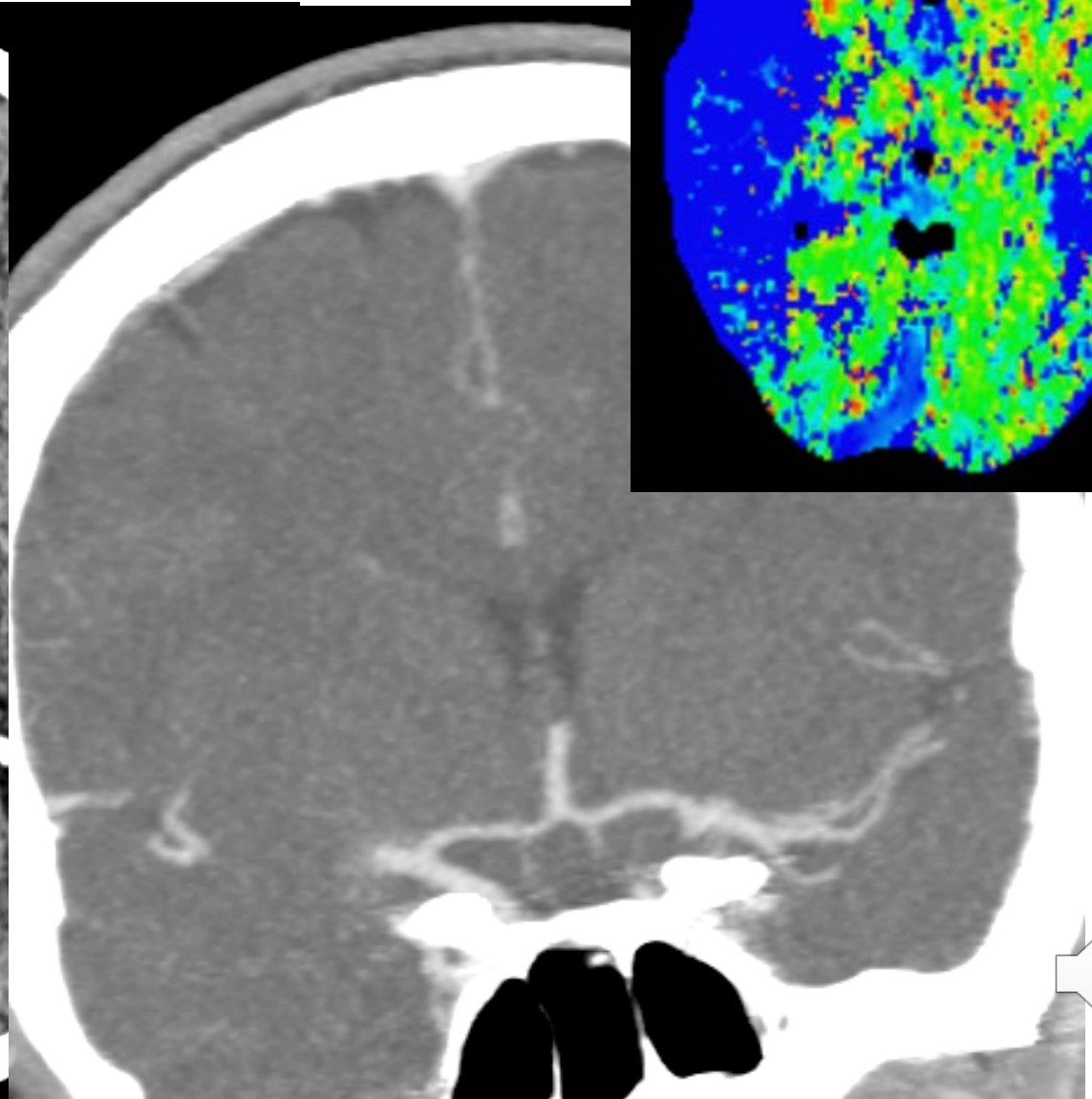

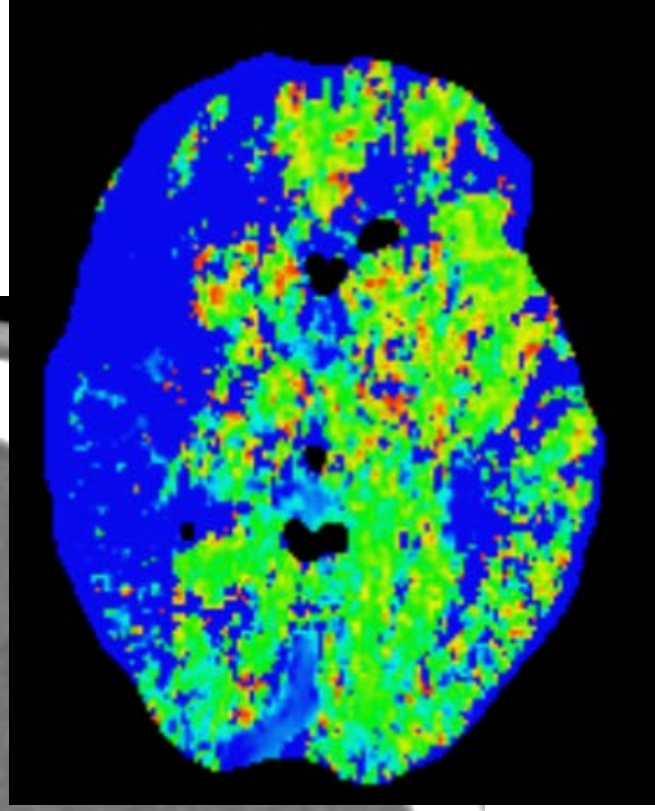

IV Lysetherapie, Angio ohne ITN

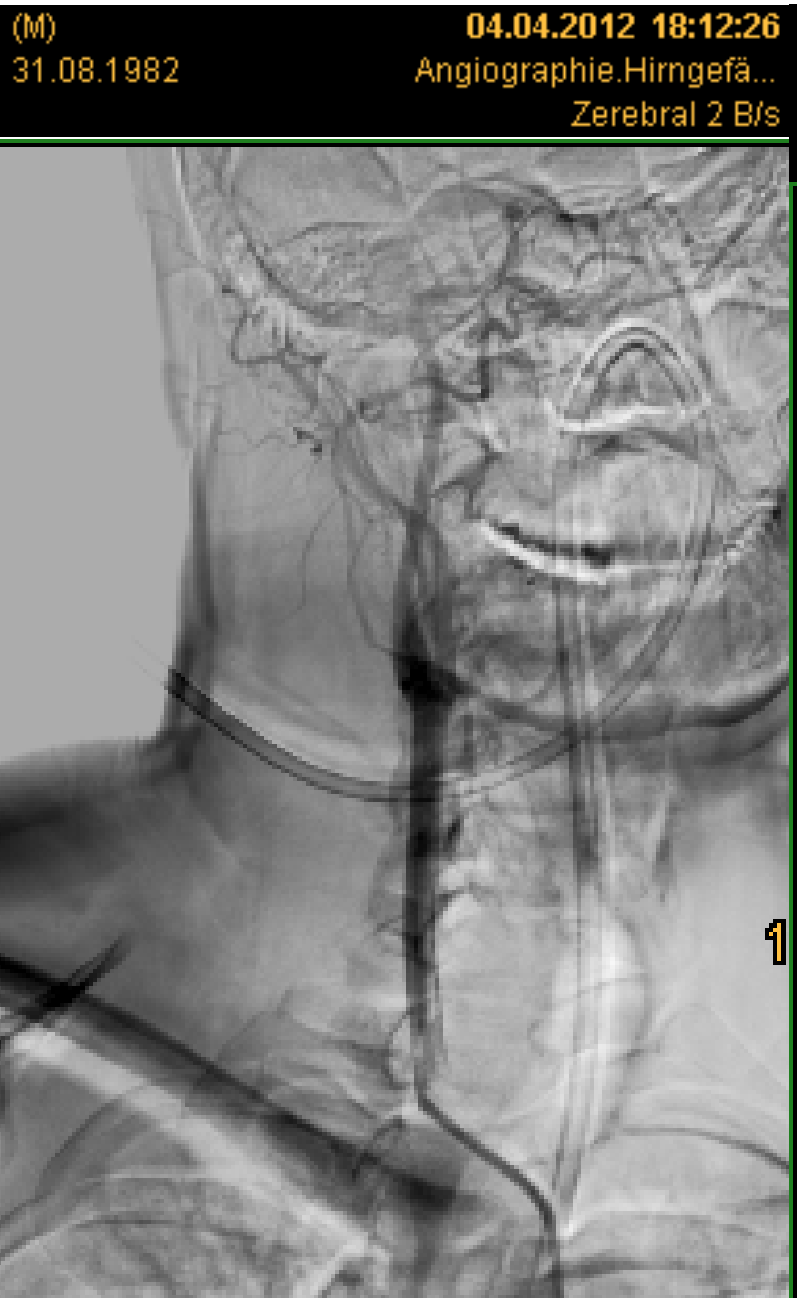

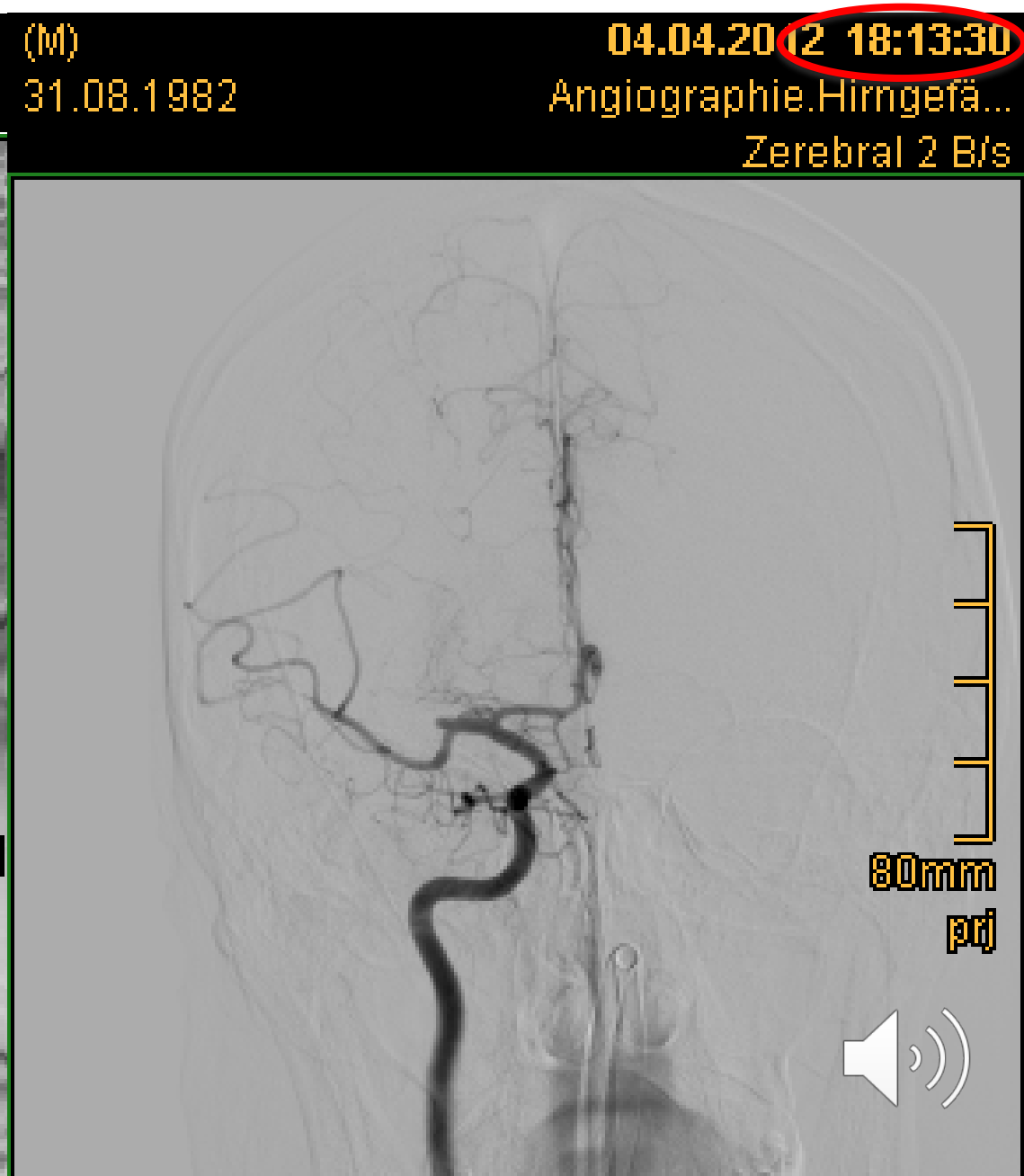

M)
1.08.1982

04.04.2012 18:16:57
Angiographie.Hirngefäße.beidse...
Navigieren

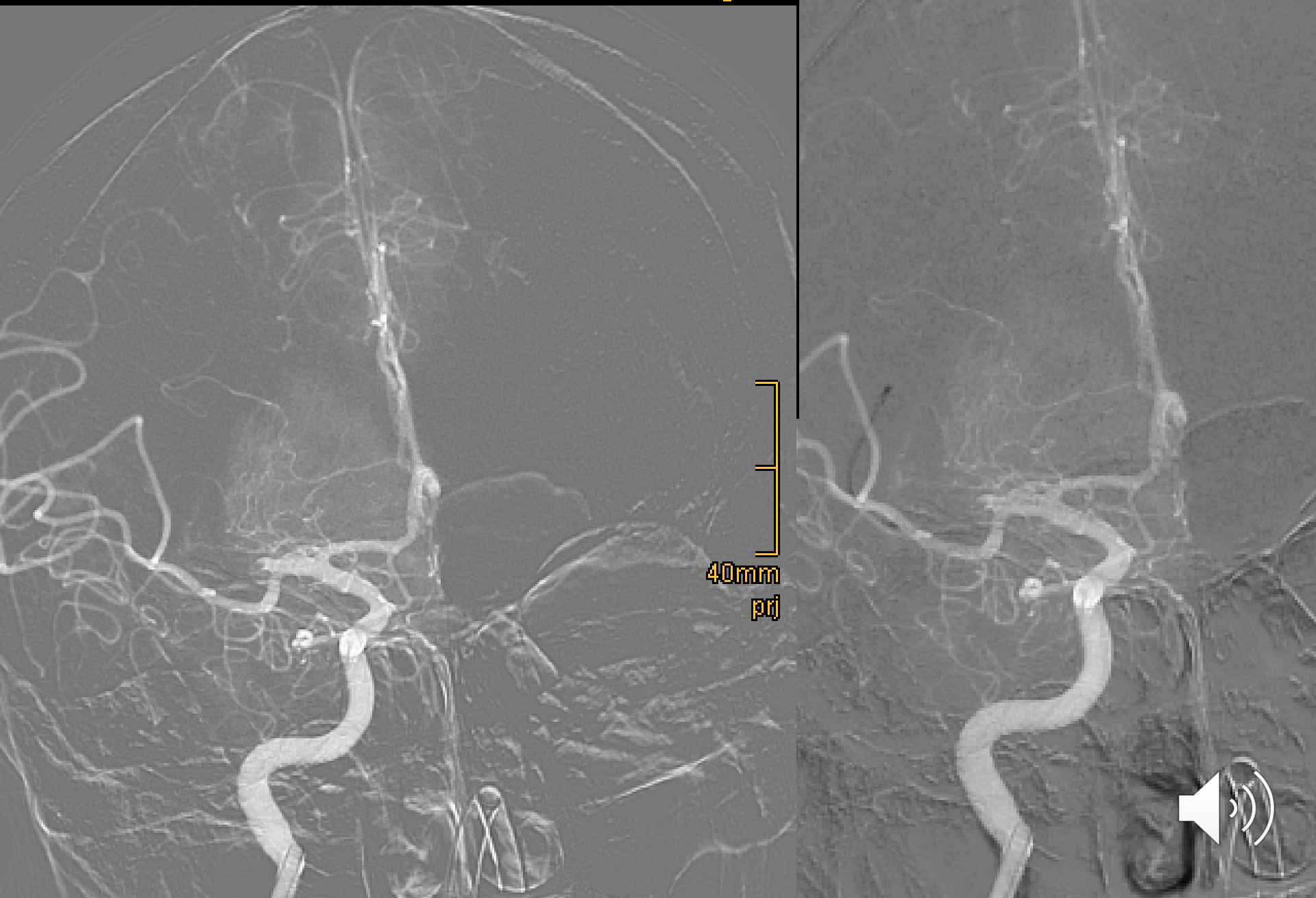

Solitaire freigesetzt

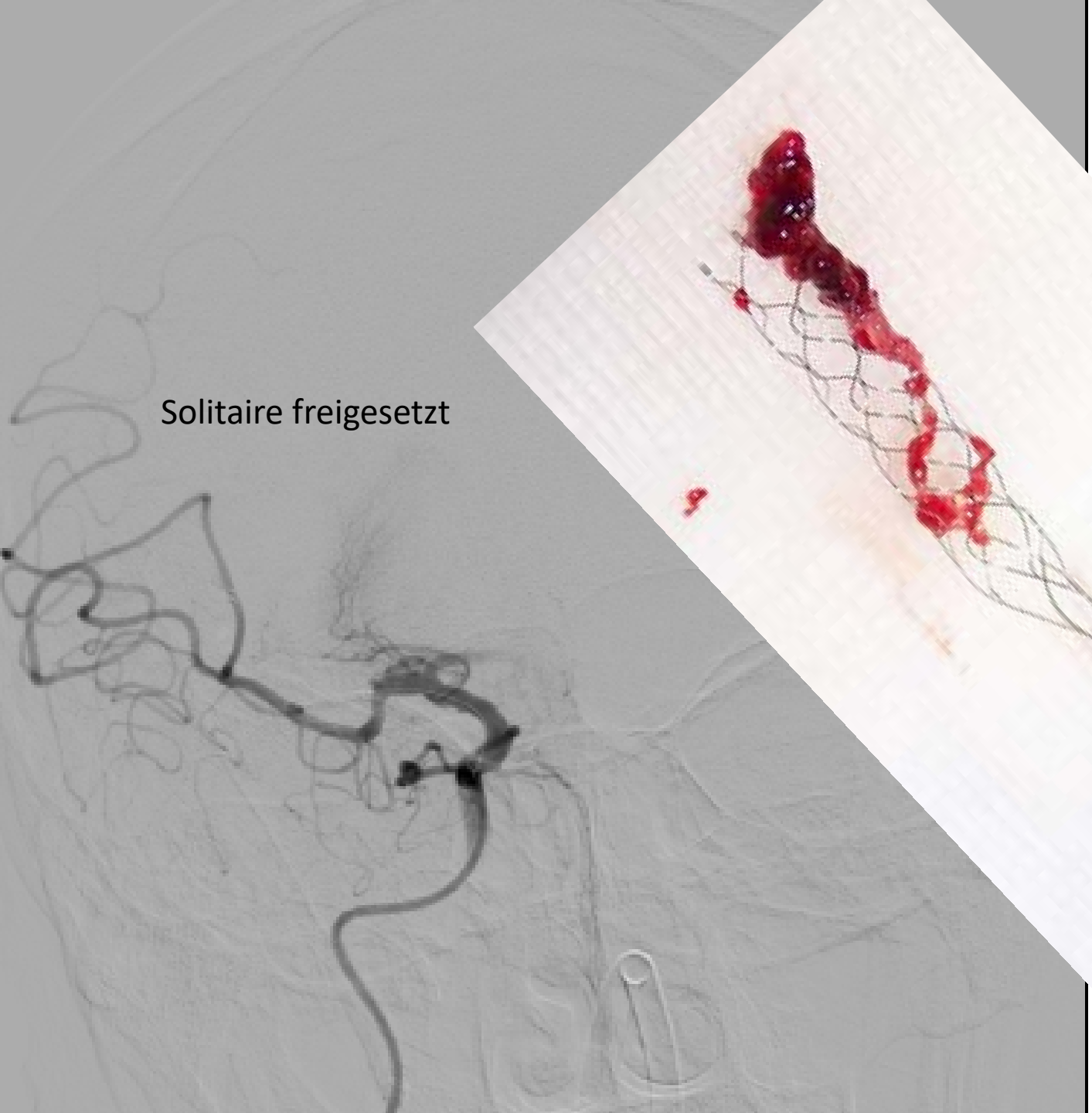

(M) 31.08.1982 (M) 31.08.1982 (M) 31.08.198 (M) 31.08.1982

04.04.2012 18:22:40

Angiographie.Hirngefäße.beidse...

Zerebral 2 B/s

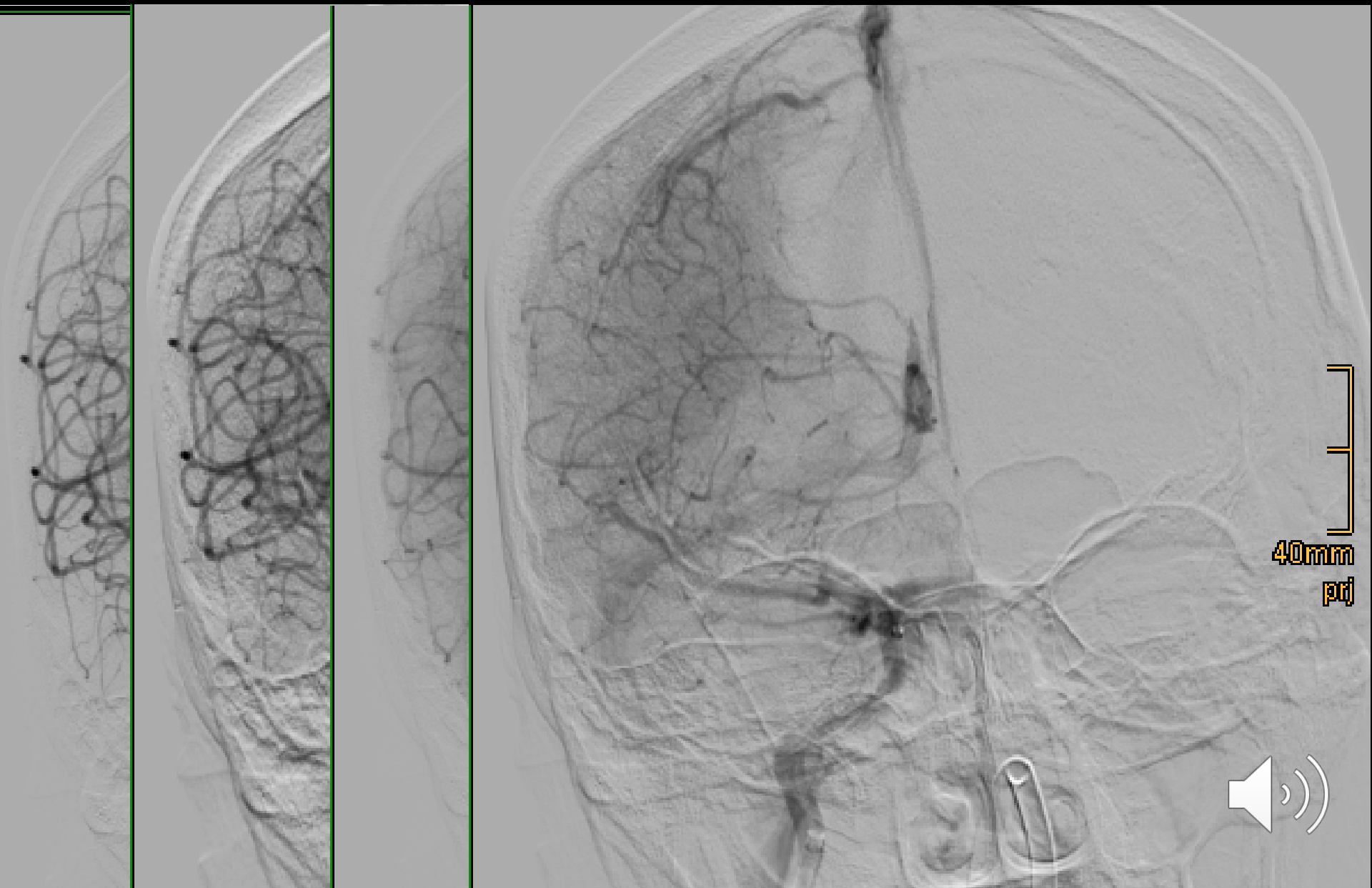

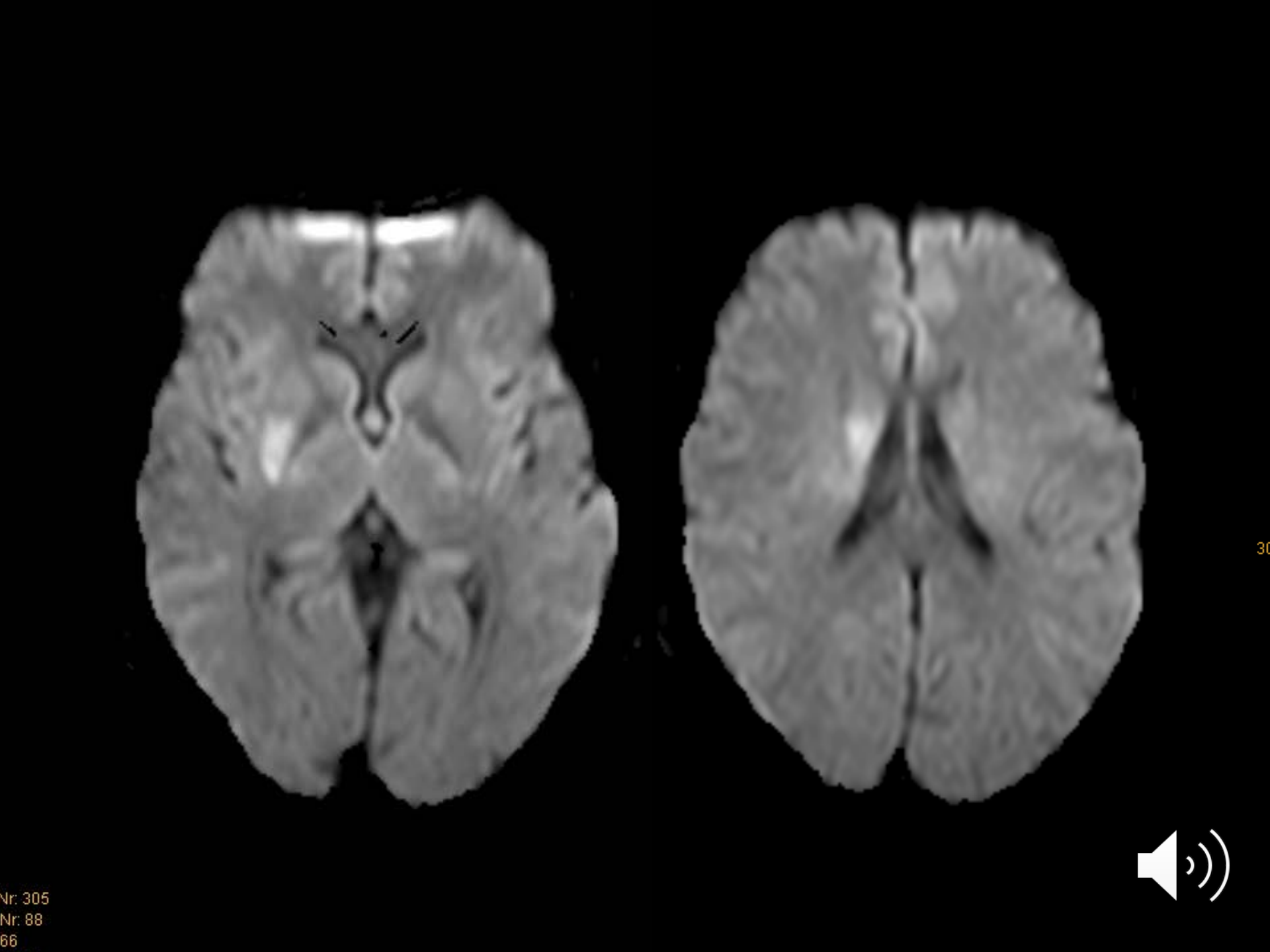
Nr: 305
Nr: 88
66

Arteriovenöse Malformation (AVM)

Komplexe (angeborene) Gefäßmissbildung:

Zuführend arterielle Feeder/ Nidus/ Drainagevenen

Gefahr: Blutung (Steal-Phänomen, Epilepsie)

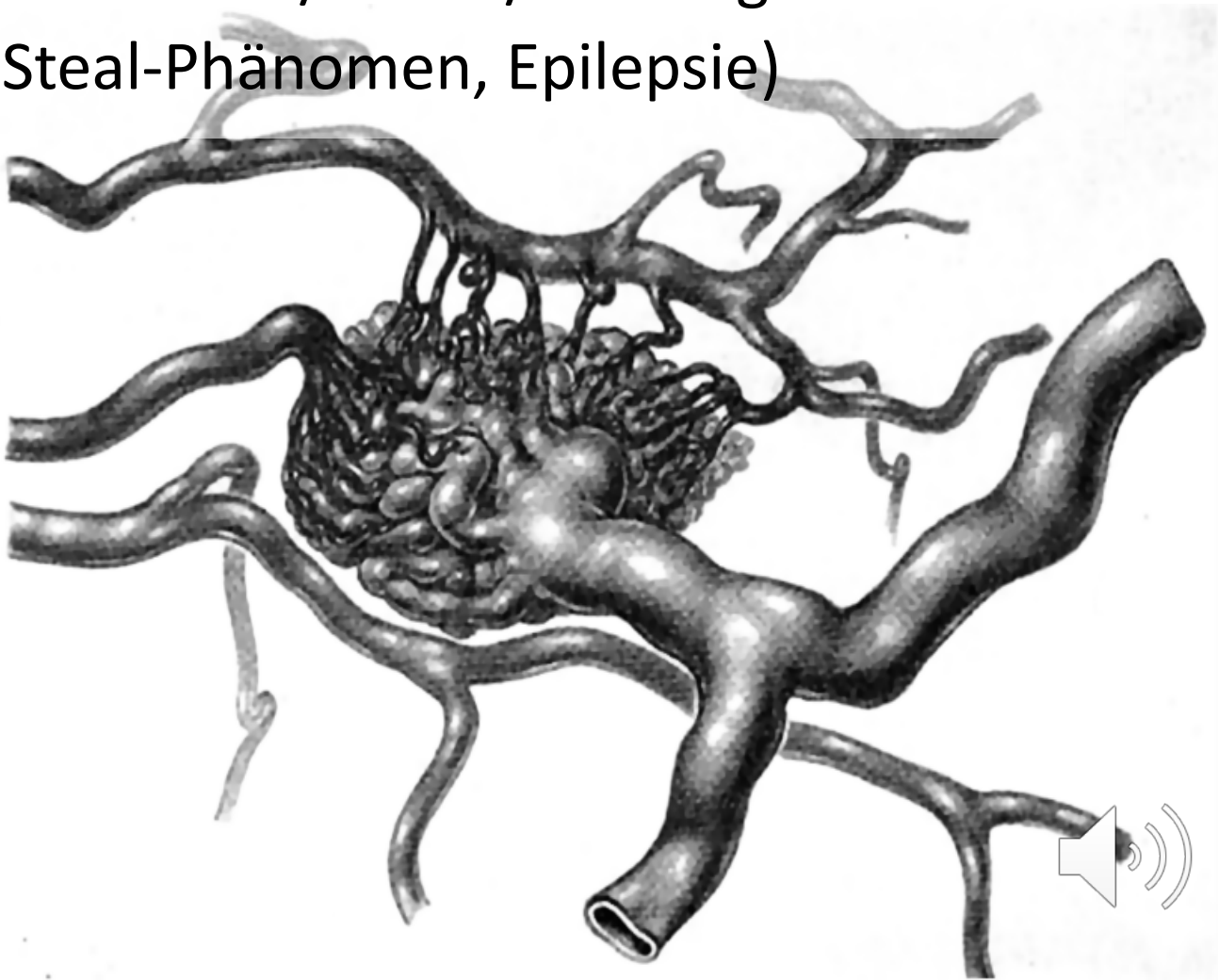

21 Jahre alte Patientin, plötzliche Kopfschmerzen, bei Aufnahme somnolent. CCT: ICB rechts parietal

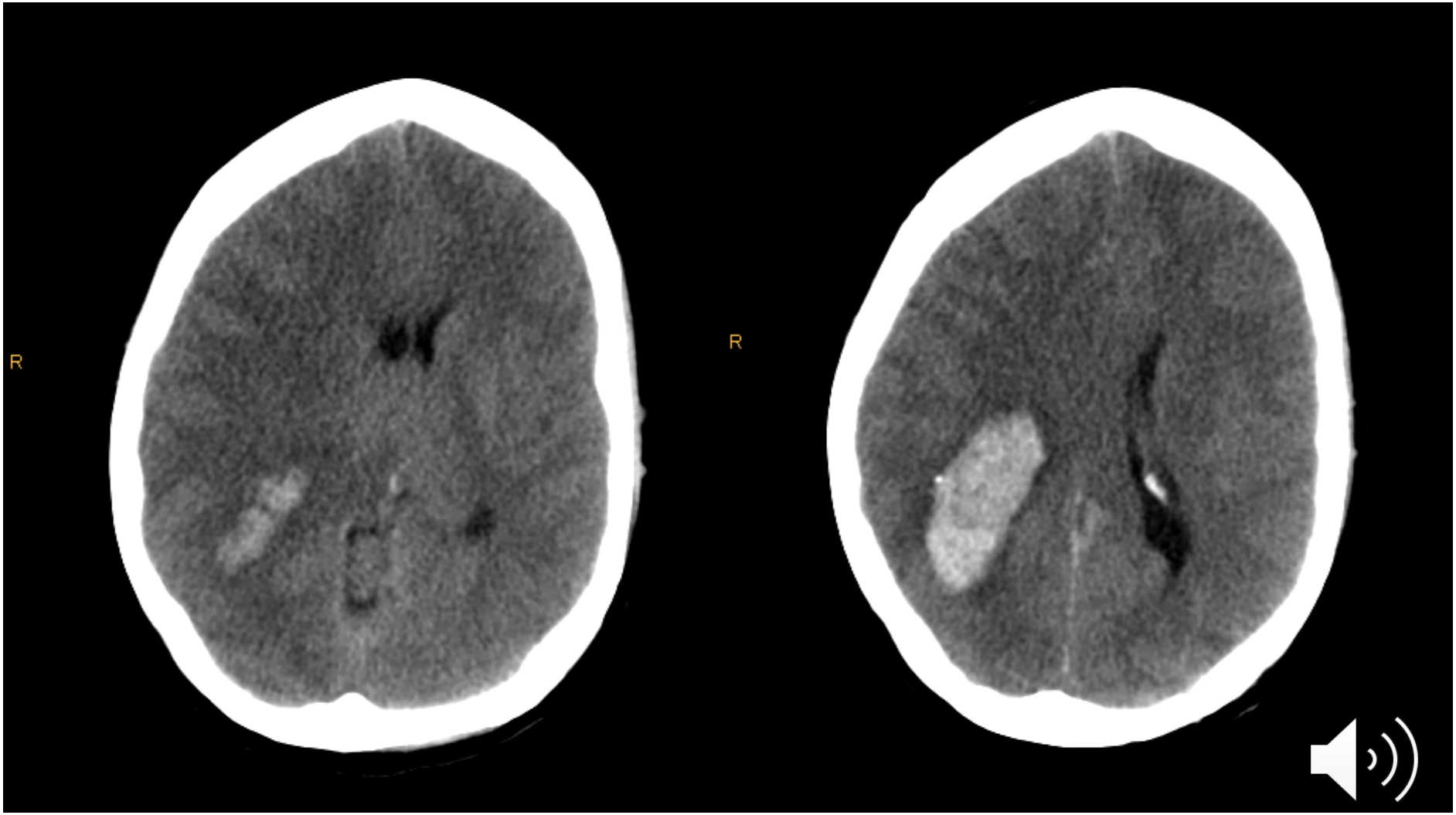

Angiografie in ITN

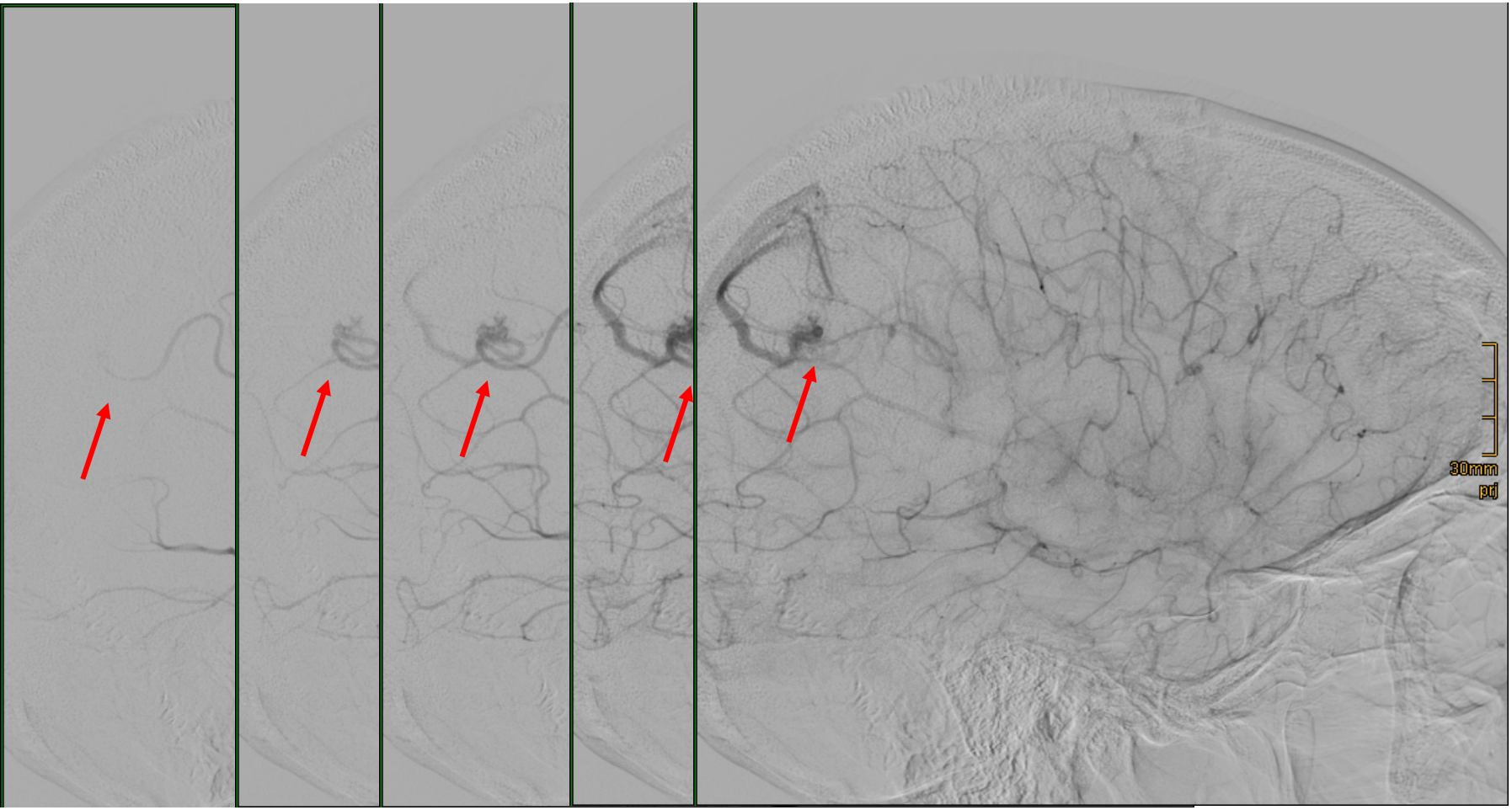

Mikrokatheterinjektion
Verschluss mit Glubran

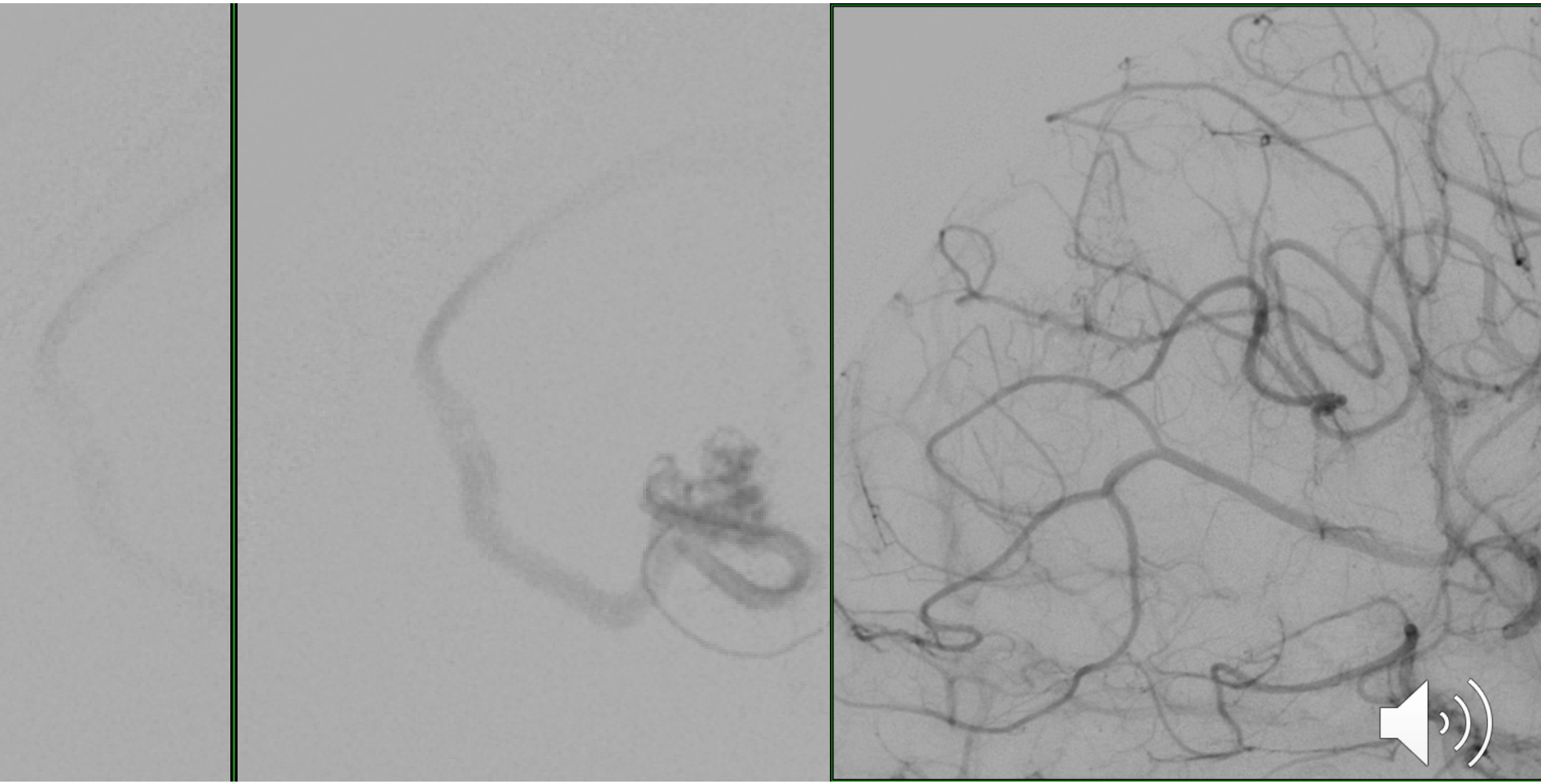

Was können wir noch....?

- Präop. Tumorembolisation (Meningeom, HNO-Tumoren, Wirbelkörpermetastasen,....)
- Embolisation von oberflächlichen Gefäßmissbildungen im Gesicht, Hals, etc.
- Embolisation von duralen AV-Fisteln
- Stents, Stents, Stents.....

Vielen Spass beim „Selbermachen“!

franziska.dorn@med.uni-muenchen.de